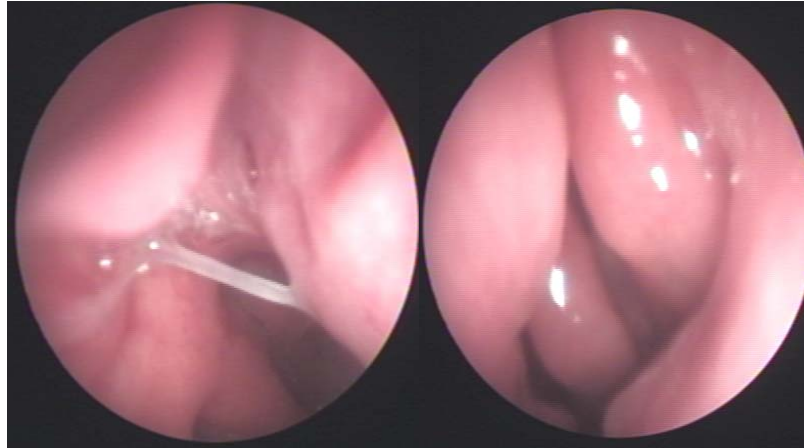


A 55 years old female presented to the center suffering from right nasal watery discharge and headache for 4 months.



Endoscopy of the nose showed:

- Right watery discharge arising from the posterior ethmoid.

Right transnasal endoscopic repair of CSF leak was performed using a graft from septal mucoperichondrium of the left side.