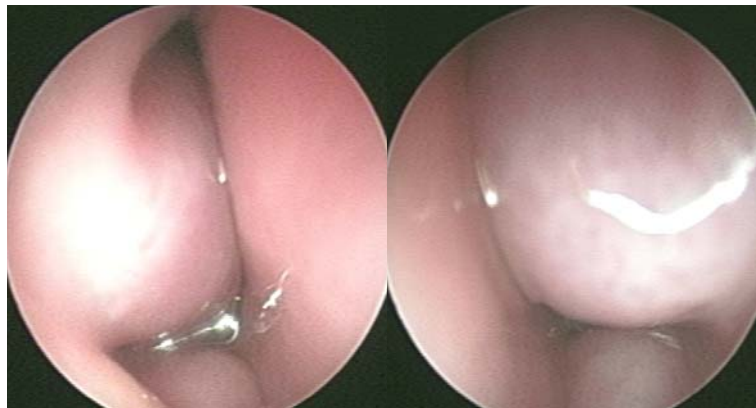


A 3 years old male presented to the center suffering from bilateral nasal obstruction.



Endoscopy of the nose and nasopharynx showed:

- Bilateral obstructed nose.
- Nasopharynx couldn't be visualized

Right transnasal endoscopic neochoana creation was performed