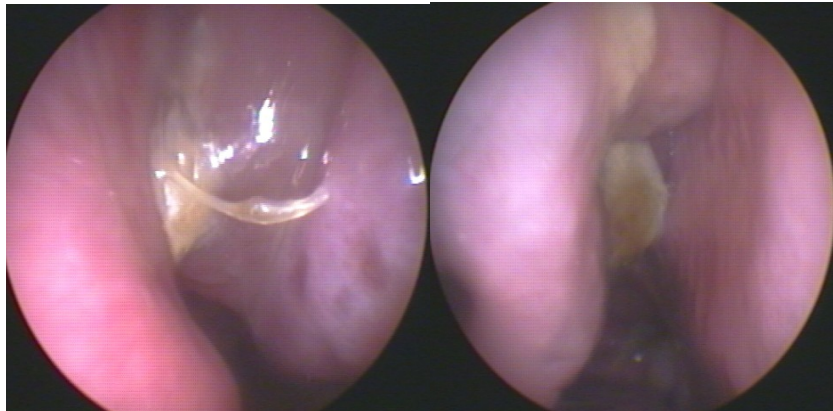


A female patient, Aged 62 years presented to the center suffering from bilateral nasal obstruction, discharge and headache for years. She has history of previous nasal operation with no operative details.



Endoscopy of the nose showed:

- Bilateral hypertrophied inferior turbinate.
- Bilateral extensive sinonasal polyposis

CT report is included.

Impression:

Mrs Hamad is suffering from allergic fungal sinusitis. bilateral functional endoscopic sinus surgery was performed.