ENDOSCOPIC ANATOMY OF THE LATERAL NASAL WALL, OSTIOMEATAL COMPLEX AND ANTERIOR SKULL BASE

A Step-by-Step Guide

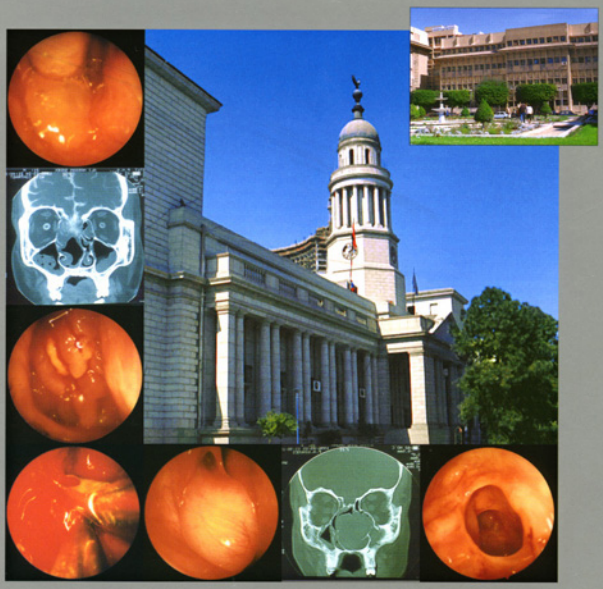

Prof. Reda KAMEL, M.D.

Professor of Rhinology
Department of ENT, Cairo University, Egypt

WITH COMPLIMENTS
OF KARL STORZ

ENDOSCOPIC ANATOMY OF THE LATERAL NASAL WALL, OSTIOMEATAL COMPLEX AND ANTERIOR SKULL BASE

A Step-by-Step Guide

86 Illustrations

Reda KAMEL, M.D.

Professor of Rhinology
Department of ENT, Cairo University, Egypt

Dedication

To my wife *Azza* and my daughters *Menna*, *Sara* and *Rana*.
They miss me most of the time because I am always busy in the field of endoscopic sinonasal surgery, research, teaching and clinical practice.

Reda Kamel

Endoscopic Anatomy of the Lateral Nasal Wall, Ostiomeatal Complex and Anterior Skull Base

A Step-by-Step Guide

Prof. **Reda KAMEL,** M.D.
Professor of Rhinology,
Department of ENT,
Functional and Microscopic ENT Unit
61 Canal Street – Sawares Square
Maadi 11431
Cairo, Egypt

Phone: +20 23 80 29 55
+20 23 63 25 96
Fax: +20 23 59 6740
E-mail: rkamel55@hotmail.com
rkamel@mednet2.camed.eun.eg

© 2006 **Endo-Press™,** Tuttlingen
ISBN 3-89756-065-8, Printed in Germany
P.O. Box, D-78503 Tuttlingen, Germany
Phone: +49/7461/14590
Fax: +49/7461/708-529
E-mail: Endopress@t-online.de

Please note:

Medical knowledge is ever changing. As new research and clinical experience broaden our knowledge, changes in treatment and drug therapy may be required. The authors and editors of the material herein have consulted sources believed to be reliable in their efforts to provide information that is complete and in accordance with the standards accepted at the time of publication. However, in view of the possibility of human error by the authors, editors, or publisher of the work herein, or changes in medical knowledge, neither the authors, editors, publisher, nor any other party who has been involved in the preparation of this work, warrants that the information contained herein is in every respect accurate or complete, and they are not responsible for any errors or omissions or for the results obtained from use of such information. The information contained within this brochure is intended for use by doctors and other health care professionals. This material is not intended for use as a basis for treatment decisions, and is not a substitute for professional consultation and/or peer-reviewed medical literature.

Some of the product names, patents, and registered designs referred to in this booklet are in fact registered trademarks or proprietary names even though specific reference to this fact is not always made in the text. Therefore, the appearance of a name without designation as proprietary is not to be construed as a representation by the publisher that it is in the public domain.

Editions in languages other than English and German are in preparation. For up-to-date information, please contact **Endo-Press™** Tuttlingen, Germany, at the address mentioned above.

Typesetting and Lithography:
Andy Ziegler Typography
D-78054 VS-Schwenningen, Germany
Eller repro+druck
D-78056 VS-Schwenningen, Germany

Printed by:
Straub Druck+Medien AG
D-78713 Schramberg, Germany

10.06-2

All rights reserved. No part of this publication may be translated, reprinted or reproduced, transmitted in any form or by any means, electronic or mechanical, now known or hereafter invented, including photocopying and recording, or utilized in any information storage or retrieval system without the prior written permission of the copyright holder.

Contents

Preface and Acknowledgements 6
1.0 Anatomical Basics
1.1 Nasal Turbinates 7
1.2 Paranasal Sinuses 8
1.3 The Ostiomeatal Complex 9
1.4 Uncinate Process 12
1.5 Bulla Ethmoidalis
1.6 Hiatus Semilunaris Inferior 13
1.7 Ethmoid Infundibulum
1.8 Hiatus Semilunaris Superior
1.9 Lateral Sinus 15
1.10 Maxillary Sinus Ostium
1.11 Fontanelle Area 16
1.12 Frontal Recess 17
1.13 Supraorbital Ethmoid Air Cell
1.14 Anterior Ethmoid Artery 18
1.15 Frontal Sinus Ostium
1.16 Agger Nasi Cell 19
1.17 Frontal Cells 20
1.18 Middle Turbinate 21
1.19 Basal Lamella 23
1.20 Ethmoid Labyrinth
1.21 Roof of the Ethmoids
1.22 Lateral Lamella
1.23 Cribriform Plate 24
1.24 Olfactory Fossa 25
1.25 Posterior Ethmoid Cells 26
1.26 Sphenoethmoidal Cell (Onodi Cell) 28
1.27 Sphenopalatine Foramen
1.28 Sphenoid Sinus 29
1.29 Neurovascular Relationships of the Sphenoid Sinus
1.30 Sphenoid Sinus Ostium 30
1.31 Nasopharynx
1.32 Nasal Choana 31
1.33 Anatomic Variations 32
1.34 Conclusion
Suggested Reading 34
Instrument Sets for Endoscopic Diagnosis and Surgery of the Lateral Nasal Wall, Ostiomeatal Complex and Anterior Skull Base as recommended by Prof. Reda Kamel, M.D. . . . 35

Preface

Transnasal endoscopic sinonasal surgery has become a widely accepted technique over the past decade. Though the technique usually is applied in the case of relatively minor diseases, it can involve major complications. It can be said with certainty that incomplete surgery is safe but ineffective, whereas complete surgery is effective but unsafe. The surgeon requires a sound background knowledge of the anatomical details of the sinonasal area in order to perform safe and effective surgery.

This booklet is an anatomic guide based on 14 years of academic and clinical experience gained by the author in transnasal endoscopic sinonasal surgery.

The aim of this volume is to impart basic information of the anatomy of the lateral nasal wall and Ostiomeatal area in a step-by-step manner. As such, it may serve as a ready reference for residents in training and practitioners of continuing medical education courses. For this reason, details of particular significance for dissection or actual surgical procedures are illustrated by schematic drawings. The author hopes that this manual will be a source of valuable information to its readers.

Reda Kamel, M.D.
Professor of Rhinology
Cairo University, Egypt, 2002

Acknowledgements

I would like to acknowledge the continuous support and encouragement I have received from the KARL STORZ company and especially from Mrs. *Sybill Storz*. I would also like to thank Professor *Heinz Stammberger* who put me on the right track during his visit to Cairo, Egypt in 1986 and my visit to Graz, Austria in 1987. He aroused my interest in endoscopic sinus surgery and gave me continuous inspiration. I am grateful to Professor *David Kennedy* who offered me invaluable support during my fellowship at the Johns Hopkins University, USA in 1989-1990. He was an excellent guide in both research and clinical fields.

I would also like to thank my senior professors at Cairo University as well as my colleagues for their continuous support, encouragement, and guidance. Moreover, I have to confess that I owe much to those dear colleagues who attended my instructive sinonasal endoscopic courses. Whilst I did my best to teach them with sincerity, their fruitful questions and discussions also taught me a lot in return.

I have to thank Dr. *Tarek Kandiel*, Dr. *Ashraf Khaled*, Dr. *Hany El Gamal*, Dr. *Hesham Abd El-Wahed* and Dr. *Mohammad Makhdoum* for their help in editing and reviewing this book.

Reda Kamel

1.0 Anatomical Basics

Before commencing to study the detailed anatomy of the lateral nasal wall, one must be aware that there is a very wide range of possible anatomic variations, both between different people and even between the two sides of the same individual's nose. It is crucial for the surgeon to be able to identify any anatomic variation and/or pathological anomaly in the individual patient to ensure that the endoscopic sinus surgery is both efficacious and safe, and affords the desired optimal benefit for the patient. The identification of variations and pathologies must be based on a very detailed and thorough understanding of the usual anatomy of the **ostiomeatal complex, lateral nasal wall** and **anterior skull base.**

1.1 Nasal Turbinates

The lateral nasal wall is characterized by three turbinates (inferior, middle, and superior), each of which has its own meatus (inferior, middle and superior meatus) running below the structure. The spheno-ethmoidal recess is located just above, posterior and medial to the superior turbinate (**Figs. 1a, b**).

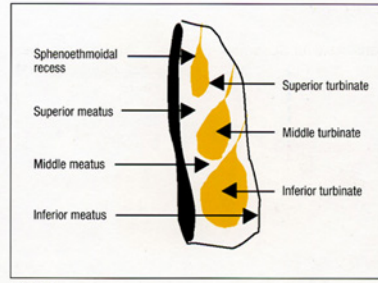

Fig. 1a
Lateral nasal wall – nasal turbinates (schematic depiction, coronal plane)

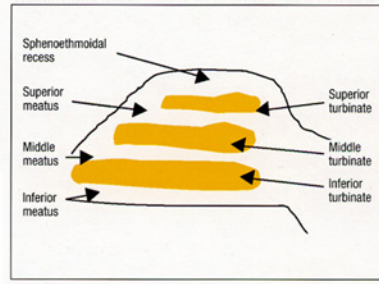

Fig. 1b
Lateral nasal wall – nasal turbinates (schematic depiction, sagittal plane).

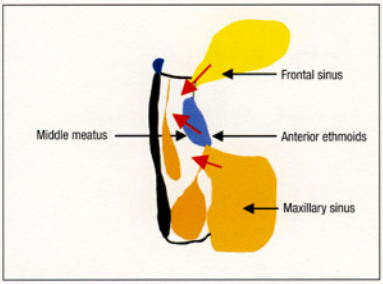

Fig. 2a
Drainage of the anterior paranasal sinuses (schematic depiction, coronal plane).

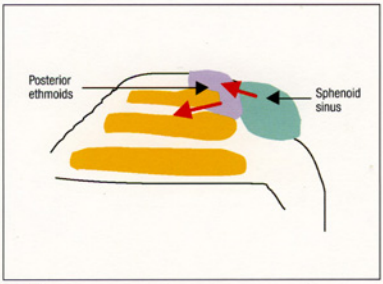

Fig. 2b
Drainage of the posterior paranasal sinuses (schematic depiction, sagittal plane).

1.2 Paranasal Sinuses

The frontal sinus, maxillary sinus and anterior ethmoid sinuses constitute the anterior group of the paranasal sinuses, all of which open into the middle meatus, while the posterior ethmoid cells and sphenoid sinus form the posterior group of the paranasal sinuses. The posterior ethmoids open into the superior meatus and the sphenoid sinus opens into the spheno-ethmoidal recess (**Figs. 2a, b**).

1.3 The Ostiomeatal Complex

The **Ostiomeatal Complex** (**OMC**) is also termed Anterior Ethmoid Middle Meatus Complex. The ostiomeatal complex consists of the air cells of the anterior ethmoid and their ostia, ethmoidal infundibulum, maxillary ostium, frontal ostium, and middle meatus. As a functional entity, the OMC represents the final section of the common drainage and ventilation pathway of the frontal, maxillary and anterior ethmoid sinuses (**Figs. 3a, b, c**).

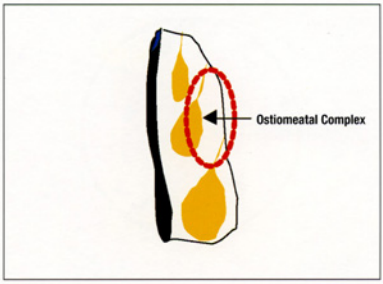

Fig. 3a
Left Ostiomeatal Complex (schematic depiction, coronal plane).

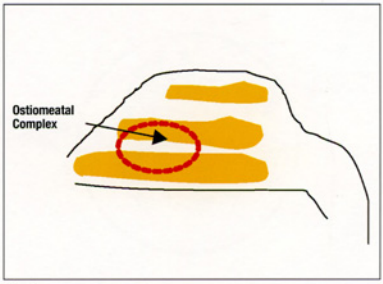

Fig. 3b
Right Ostiomeatal Complex (schematic depiction, sagittal plane).

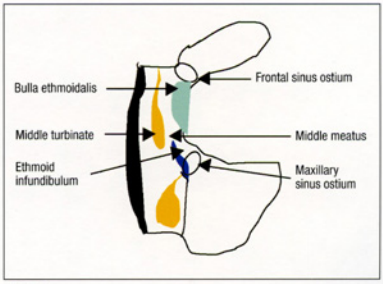

Fig. 3c
Left Ostiomeatal Complex (schematic depiction, coronal plane).

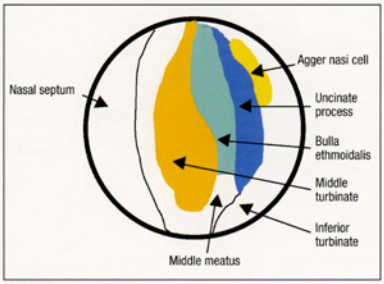

Fig. 3d
Left Ostiomeatal Complex (0°-endoscope).

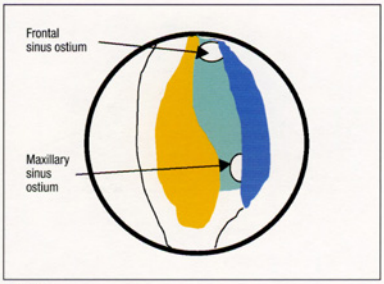

Fig. 3e
Left Ostiomeatal Complex (30°-endoscope).

The following structures can be identified under the endoscope as parts of the *Ostiomeatal Complex:*

- Agger nasi cell.
- Uncinate process.
- Bulla ethmoidalis (**Fig. 3d**).
- Hiatus semilunaris inferior between the uncinate process and bulla ethmoidalis.
- Middle turbinate.
- Location of the maxillary sinus ostium posterior and inferior to the angle formed between bulla ethmoidalis and uncinate process.
- Location of the frontal sinus ostium anterior and superior to the angle formed between bulla ethmoidalis and uncinate process (**Fig. 3e**).

Proceed by insinuating the endoscope posteriorly between the middle turbinate and the ethmoidal bulla to identify the following structures (**Figs. 3f, g, h**):

- Basal lamella (second part of the middle turbinate, oblique part).
- Hiatus semilunaris superior and lateral sinus posterior and superior to the ethmoidal bulla.

The following structures can be identified by gently pushing medially the middle turbinate (**Fig. 3i**):

- Uncinate process.
- Agger nasi cell, anterior and superior to the uncinate process.
- Bulla ethmoidalis.
- Basal lamella.

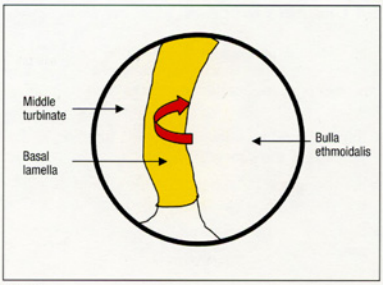

Fig. 3f
Basal lamella, (yellow area) lateral sinus and hiatus semilunaris superior (red arrow) (endoscopic view).

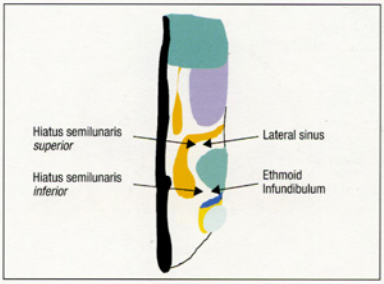

Fig. 3g
Left Ostiomeatal Complex (schematic depiction, axial plane).

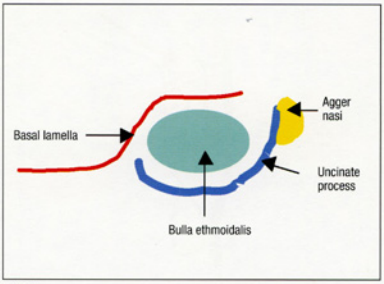

Fig. 3i
Left ostiomeatal complex (schematic depiction, sagittal plane).

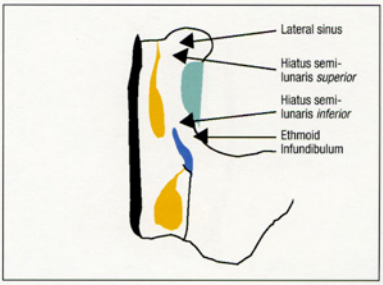

Fig. 3h
Left ostiomeatal complex (schematic depiction, coronal plane).

1.4 Uncinate Process

The uncinate process is a thin bone located in a sagittal orientation and shaped like a hook. The uncinate process is attached to the following structures:

- Inferiorly and far posterior: to the ethmoid process of the inferior turbinate.
- Anteriorly and far superior: to the lamina papyracea, skull base or middle turbinate.
- Laterally: to the lamina papyracea and fontanelle area.

Its free posterior rim constitutes the free edge of the hiatus semilunaris inferior leading to the ethmoid infundibulum (**Fig. 4a**).

Superior attachment of the uncinate process: the uncinate process usually is attached to the lamina papyracea, whereas the ethmoidal infundibulum ends blindly in the terminal recess. Under these circumstances, the frontal recess opens directly into the middle meatus (**Fig. 4b**). Alternatively, the uncinate process may be attached to the skull base or the neck of the middle turbinate, a configuration where the frontal recess opens into the ethmoidal infundibulum (**Figs. 4c, d**).

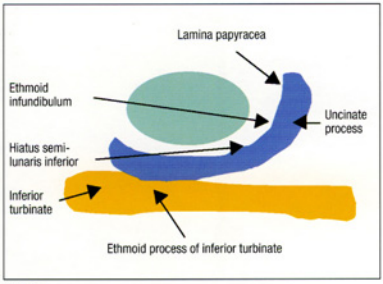

Fig. 4a
Left uncinate process (schematic depiction, sagittal plane).

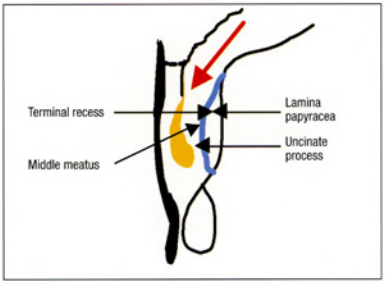

Fig. 4b
Uncinate process attached to lamina papyracea (terminal recess) (schematic depiction, coronal plane).

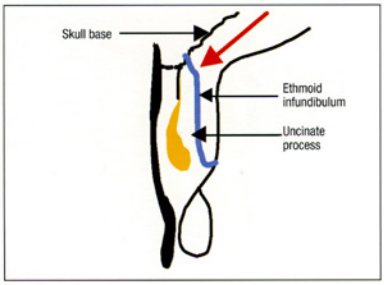

Fig. 4c
Uncinate process attached to the skull base (schematic depiction, coronal plane).

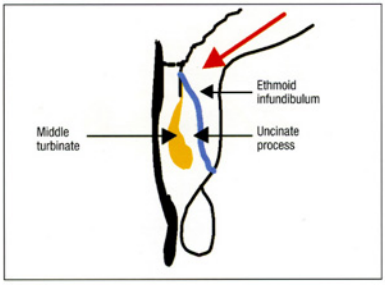

Fig. 4d
Uncinate process attached to the middle turbinate (schematic depiction, coronal plane).

1.5 Bulla Ethmoidalis

The bulla ethmoidalis (**Figs. 5a, b, c**) is a part of the air cells of the anterior ethmoid. It is attached laterally to the lamina papyracea and usually opens into the lateral sinus posteriorly. The spatial relationships can be summarized as follows:

- Anteriorly and inferiorly: the ethmoid infundibulum separates the bulla from the uncinate process.
- Superiorly: the suprabullar recess (the anterior and superior portion of the lateral sinus) separates the bulla from the fovea ethmoidalis.
- Posteriorly: the retrobullar recess (the posterior and inferior part of the lateral sinus) separates the bulla from the basal lamella of the middle turbinate.
- Medially: the middle meatus separates the bulla from the middle turbinate. The lumen between bulla ethmoidalis and middle turbinate is termed the conchal sinus.

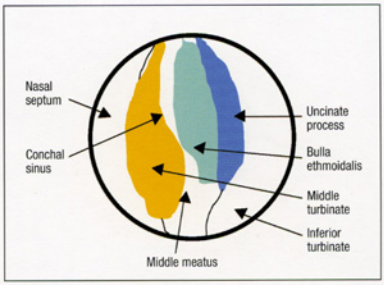

Fig. 5a
Left bulla ethmoidalis (endoscopic view).

1.6 Hiatus Semilunaris Inferior

The hiatus semilunaris inferior is a two-dimensional passage-way between the ethmoidal bulla and the free edge of the uncinate process, and leads to a three-dimensional lumen, (i.e. the ethmoidal infundibulum) between the anterior wall of the ethmoidal bulla and the posterior wall of the uncinate process.

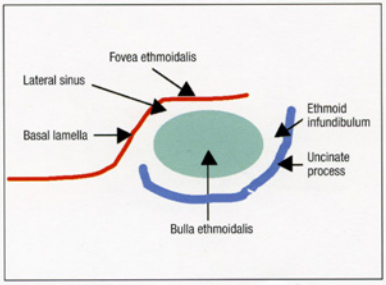

Fig. 5c
Bulla ethmoidalis (schematic depiction, sagittal plane).

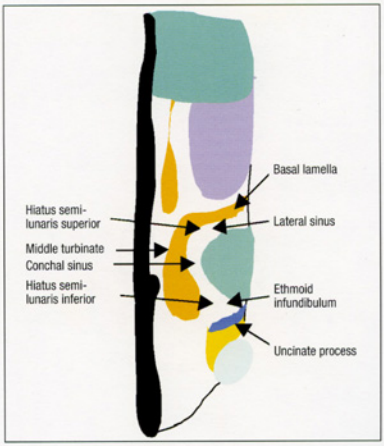

Fig. 5b
Left bulla ethmoidalis (schematic depiction, axial plane).

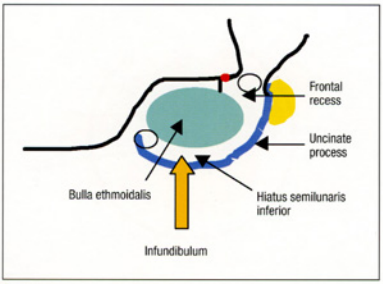

Fig. 7
Left hiatus semilunaris inferior and ethmoid infundibulum (schematic depiction, sagittal plane).

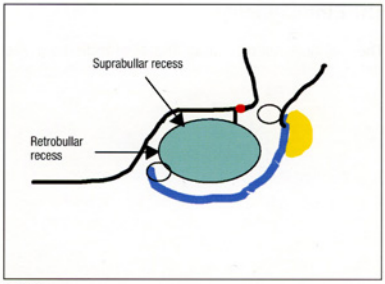

Fig. 9a
Lateral sinus components: Suprabullar recess and retrobullar recess (schematic depiction, sagittal plane).

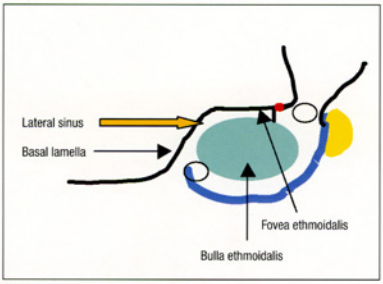

Fig. 8a
Lateral sinus and hiatus semilunaris superior (schematic depiction, sagittal plane).

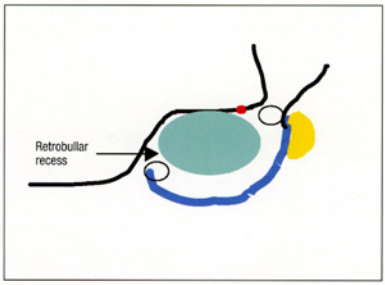

Fig. 9b
Lateral sinus: no suprabullar recess (schematic depiction, sagittal plane).

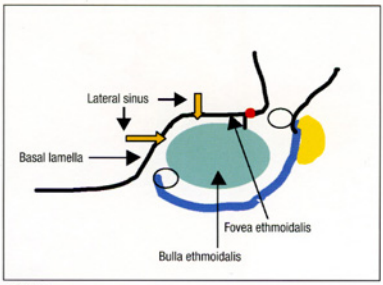

Fig. 8b
Lateral sinus and hiatus semilunaris superior (schematic depiction, sagittal plane).

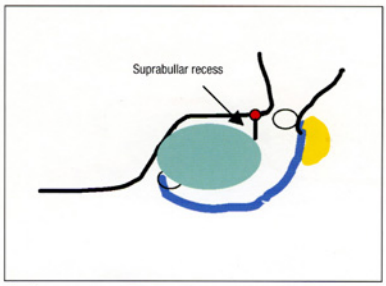

Fig. 9c
Lateral sinus: no retrobullar recess (schematic depiction, sagittal plane).

1.7 Ethmoid Infundibulum

The boundaries of the ethmoid infundibulum are defined as follows:

- Anteriorly: uncinate process.
- Posteriorly: anterior wall of the bulla ethmoidalis.
- Laterally: lamina papyracea anteriorly and fontanelle area posteriorly.
- Medially: hiatus semilunaris inferior and uncinate process.
- Anteriorly and superiorly: frontal recess area and frontal sinus ostium.
- Posteriorly and inferiorly: maxillary sinus ostium (**Fig. 7**).

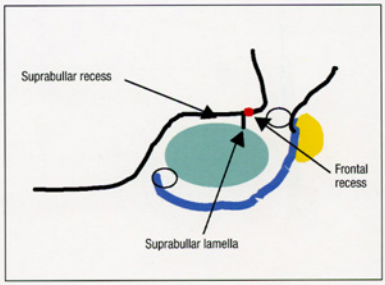

Fig. 9d
Left suprabullar lamella (schematic depiction, sagittal plane).

1.8 Hiatus Semilunaris Superior

The hiatus semilunaris superior is a two-dimensional passage-way between the ethmoidal bulla (anteriorly and inferiorly) and the skull base (superiorly) and the basal lamella (posteriorly), and leads to a three-dimensional lumen, i.e. the lateral sinus (**Figs. 8a, b**).

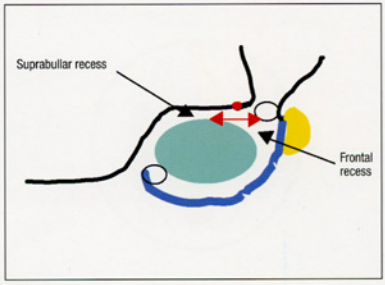

Fig. 9e
In the absence of a suprabullar lamella the lateral sinus and frontal recess form a continuous cavity (schematic depiction, axial plane).

1.9 Lateral Sinus

The lateral sinus is divided into a suprabullar recess and a retrobullar recess. In its anterior and superior location, the suprabullar recess is a space bordered by the ethmoidal bulla (inferiorly) and the ethmoidal fovea (superiorly). In contrast, the retrobullar recess in its posterior and inferior location is bordered by the ethmoidal bulla (anteriorly) and the basal lamella (posteriorly). If the ethmoidal bulla directly adheres to the ethmoidal fovea, no suprabullar recess is formed, whereas there is no retrobullar recess, if the ethmoidal bulla adheres to the basal lamella (**Figs. 9a, b, c**).

Far anterior, the suprabullar recess of the lateral sinus is separated from the frontal recess by the suprabullar lamella. In the absence of a suprabullar lamella the suprabullar recess of the lateral sinus and the frontal recess of the infundibulum form a continuous cavity (**Figs. 9d, e**).

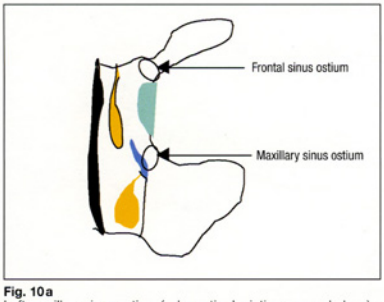

Fig. 10a
Left maxillary sinus ostium (schematic depiction, coronal plane).

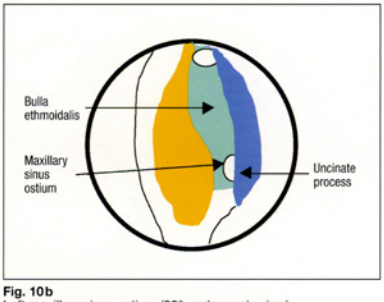

Fig. 10b
Left maxillary sinus ostium (30°-endoscopic view).

1.10 Maxillary Sinus Ostium

The maxillary sinus ostium usually is located posterior and inferior at the angle formed by the ethmoidal bulla and the uncinate process. Size, exact location, shape, and orientation of the maxillary sinus ostium are subject to anatomic variations (**Figs. 10a, b**).

1.11 Fontanelle Area

The medial wall of the maxillary sinus is composed of bone with nasal mucosa medially and maxillary sinus mucosa laterally, the area of the fontanelle being an exception. In the area of the fontanelle, the bony wall is dehiscent and the nasal mucosa adheres to the maxillary sinus mucosa. The uncinate process separates the fontanelle area into the anterior and posterior fontanelles (i.e. anterior and posterior to the uncinate process). The natural maxillary sinus ostium is located in the posterior fontanelle. There may be one or more accessory maxillary sinus ostium/ostia in the anterior and/or posterior fontanelle (**Fig. 11**).

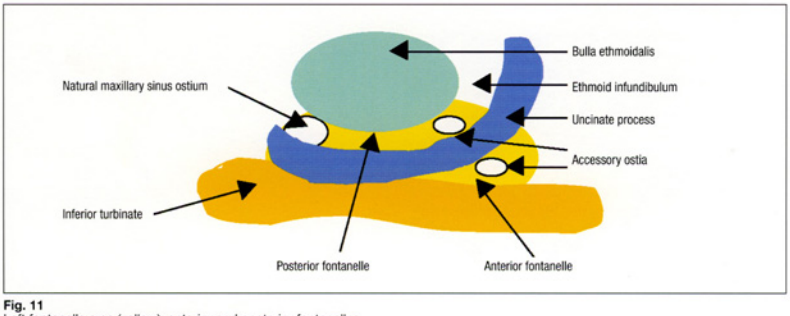

Fig. 11
Left fontanelle area (yellow): anterior and posterior fontanelles (schematic depiction, sagittal plane).

1.12 Frontal Recess

The frontal recess is a three-dimensional cavity defined by the following boundaries:

- Anteriorly: uncinate process and agger nasi cell.
- Posteriorly: bulla ethmoidalis and suprabullar lamella.
- Laterally: lamina papyracea.
- Medially: hiatus semilunaris inferior or neck of the middle turbinate.
- Inferiorly: ethmoid infundibulum.
- Superiorly: fovea ethmoidalis, supraorbital air cell, anterior ethmoid artery and frontal ostium.

The size of the frontal recess is determined by the size of the surrounding anterior ethmoid air cells namely: bulla ethmoidalis, agger nasi cell, supraorbital air cells and frontal cells. If the bulla ethmoidalis is large anteriorly and the agger nasi is large posteriorly, the frontal recess becomes very narrow and takes on the appearance of a fronto-nasal duct, which it is not (**Figs. 12a, b, c**).

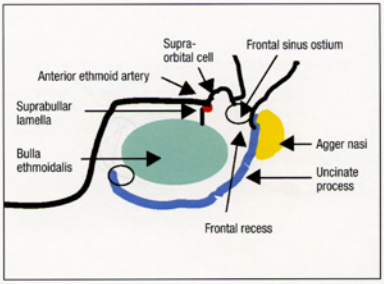

Fig. 12a
Left frontal recess (schematic depiction, sagittal plane).

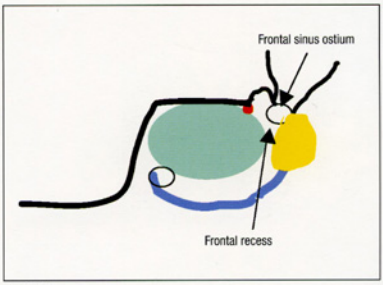

Fig. 12b
Narrow left frontal recess (this is not a fronto-nasal duct) (schematic depiction, sagittal plane).

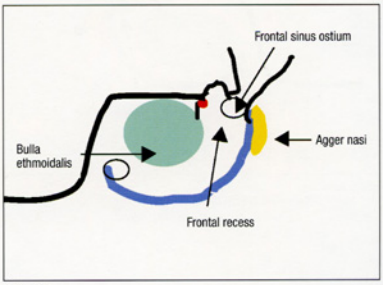

Fig. 12c
Wide left frontal recess (schematic depiction, sagittal plane).

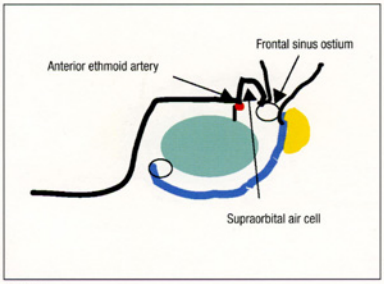

Fig. 13
Left supraorbital air cell (schematic depiction, sagittal plane).

1.13 Supraorbital Ethmoid Air Cell

The supraorbital ethmoid air cell arises from pneumatization of the orbital process of the frontal bone. It is located just posterior to the frontal sinus ostium. The anterior ethmoid artery [AEA] is present just posterior to the supraorbital cell and anterior to the suprabullar lamella in the fovea ethmoidalis. Pneumatization of the supraorbital air cell is subject to anatomic variation (**Fig. 13**).

1.14 Anterior Ethmoid Artery (AEA)

The anterior ethmoid artery is an orbital branch of the ophthalmic artery and exits the orbit through the anterior ethmoidal foramen in a medial position. From there, it passes into the orbito-cranial canal in the roof of the ethmoid, entering the lateral lamella of the cribriform plate and the olfactory fossa. Further on, the anterior ethmoid artery passes anteriorly into the ethmoidal sulcus to the cribriform plate. The vessel ultimately changes direction to run inferiorly into the cribroethmoidal canal to the nose (**Figs. 14a, b**).

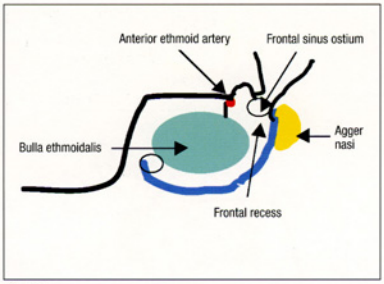

Fig. 14a
Left anterior ethmoid artery (AEA) (schematic depiction, sagittal plane).

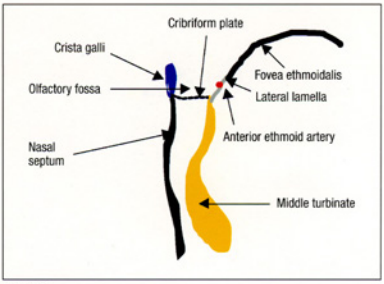

Fig. 14b
Left anterior ethmoid artery (schematic depiction, coronal plane).

1.15 Frontal Sinus Ostium

Located at the bulla-uncinate angle anteriorly and superiorly, the frontal sinus opens into the frontal recess through the frontal ostium. The frontal sinus, frontal ostium and frontal recess are distinguished by their hourglass appearance (**Fig. 15**).

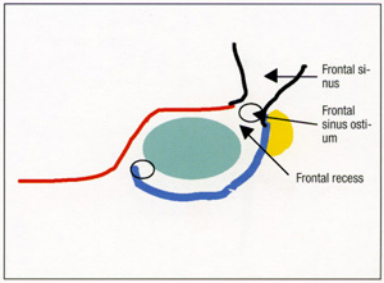

Fig. 15
Left frontal sinus ostium (schematic depiction, sagittal view).

1.16 Agger Nasi Cell

Located medial to the lacrimal sac and fossa and anterior to the uncinate process, the agger nasi cell is one of the air cells of the anterior ethmoid. The antero-medial wall of the structure can be seen through the endoscope directly anterior and superior to the neck of the middle turbinate. The postero-lateral wall of the structure is hidden by the uncinate process and constitutes the anterior wall of the frontal recess. The size of the agger nasi cell contributes to the definition of the size and shape of the frontal recess (**Figs. 16a, b**).

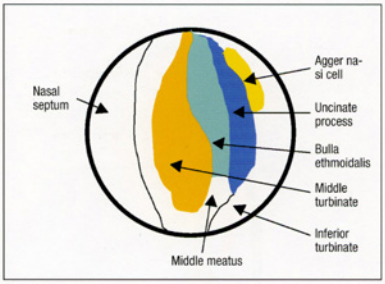

Fig. 16a
Left agger nasi cell (endoscopic view).

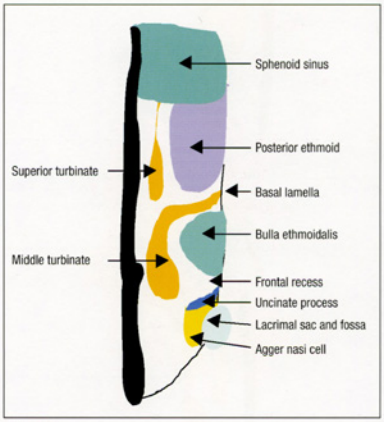

Fig. 16b
Left agger nasi cell (schematic depiction, axial view).

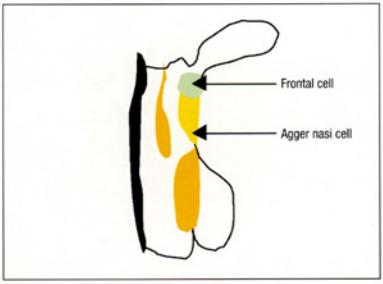

Fig. 17a
Single small left frontal cell (schematic depiction, coronal view).

1.17 Frontal Cells

The frontal cells (**Figs. 17a, b, c, d**) are anterior ethmoid air cells that pneumatize the frontal recess above the agger nasi cell. They may be:

- a single small cell above the agger nasi cell,
- multiple small cells above the agger nasi cell,
- a single large cell above the agger nasi cell extending to the frontal sinus,
- a single small cell inside the frontal sinus.

Larger sized frontal cells may compromise the nasofrontal pathway.

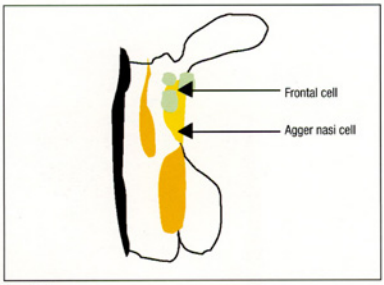

Fig. 17b
Multiple small left frontal cells (schematic depiction, coronal view).

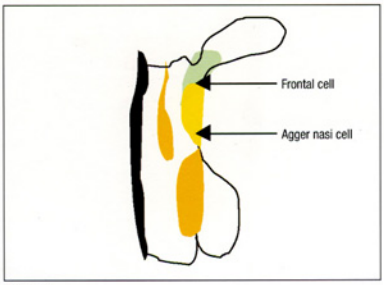

Fig. 17c
Single large left frontal cell (schematic depiction, coronal view).

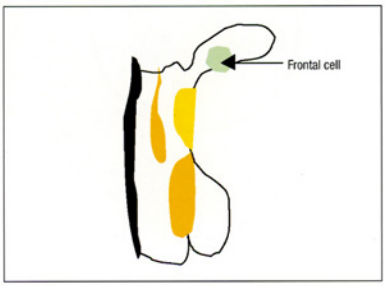

Fig. 17d
Single small frontal cell inside the left frontal sinus (schematic depiction, coronal view).

1.18 Middle Turbinate

Viewed from anterior, the middle turbinate is characterized by a conchal head, conchal neck, and conchal sinus. The conchal sinus is the cavity between the ethmoidal bulla and the middle turbinate (**Fig. 18a**). In a far anterior position, the structure is attached to the ethmoid crest of the maxillary bone and agger nasi cell. Far posteriorly, the structure is attached to the ethmoid crest of the perpendicular plate of the palatine bone. The middle turbinate consists of three discernible components (**Fig. 18b**): the first part in an anterior and medial position exhibits a sagittal plane and is attached vertically to the skull base, superiorly between the cribriform plate and the lateral lamella (**Fig. 18c**).

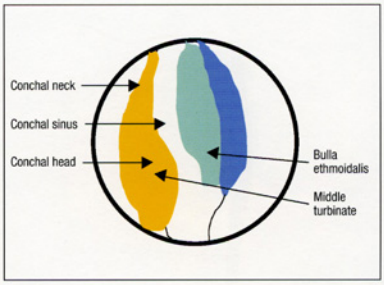

Fig 18a
Left middle turbinate (endoscopic view).

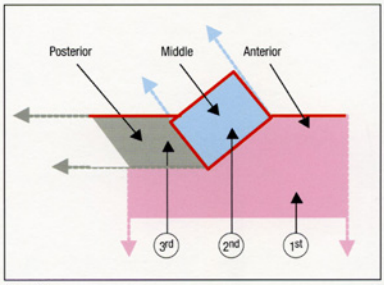

Fig. 18b
Left middle turbinate seen from its medial aspect (schematic depiction).

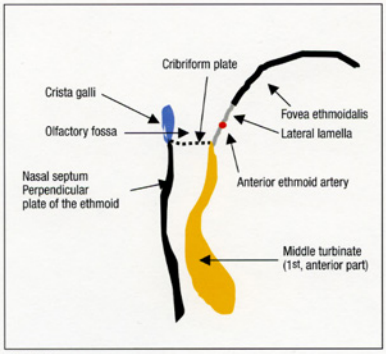

Fig. 18c
First (anterior) part of the left middle turbinate (schematic depiction, coronal view).

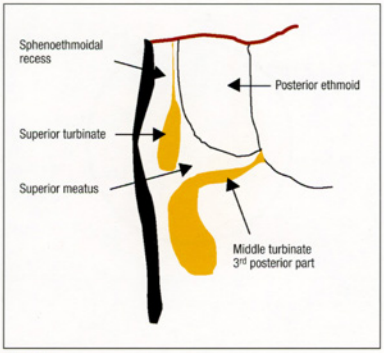

Fig 18e
Third (posterior) part of the left middle turbinate (schematic depiction, coronal view).

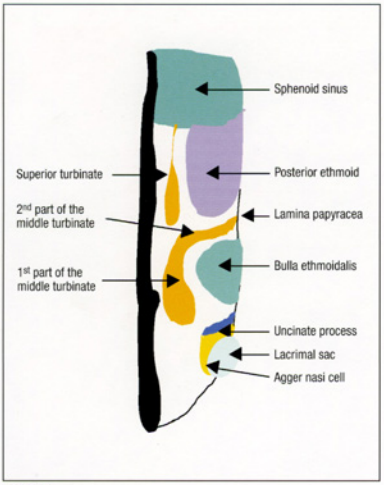

Fig. 18d
Second (middle) part of the left middle turbinate (schematic depiction, axial view).

The second part is located in the middle of the structure, exhibits a frontal plane, and is attached laterally to the lamina papyracea in an oblique fashion (**Fig. 18d**). This part of the middle turbinate is termed the basal lamella. The third part is located posteriorly, exhibits a horizontal plane and is attached laterally to the perpendicular plate of palatine bone. It forms the roof of the posterior part of the middle meatus (**Fig. 18e**).

Part	Location	Plane	Attachment
First	(anterior)	Sagittal	Skull base
Second	(middle)	Frontal	Lamina papyracea
Third	(posterior)	Horizontal	Perpendicular plate of the palatine bone

1.19 Basal Lamella

The basal lamella constitutes the middle portion of the middle turbinate and is an important landmark. It separates the anterior and posterior ethmoid air cells (**Fig. 19a**) and can be visualized by insinuating the endoscope between the middle turbinate and the ethmoidal bulla (**Fig. 19b**). The boundaries of the basal lamella are defined as follows (**Figs. 19a, b, c**):

- Superiorly: skull base (fovea ethmoidalis).
- Laterally: lamina papyracea.
- Inferiorly: the attachment of the third (posterior) part of the middle turbinate to the basal lamella.
- Medially: the attachment of the first (anterior) part of the middle turbinate to the basal lamella.

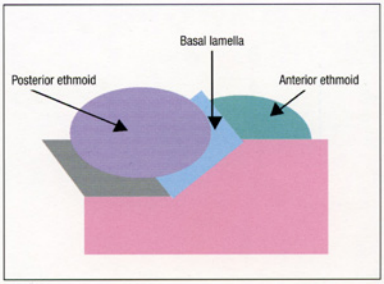

Fig. 19a
Second (middle) part of left middle turbinate (basal lamella) separates the anterior and the posterior ethmoids (schematic depiction).

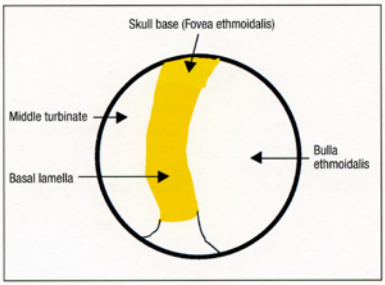

Fig. 19b
Left basal lamella seen through the middle meatus (endoscopic view).

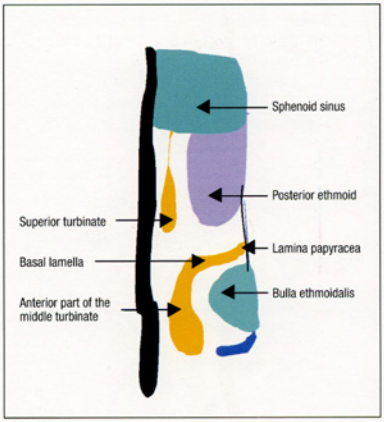

Fig. 19c
Lateral and medial attachments of the basal lamella (schematic depiction, axial view).

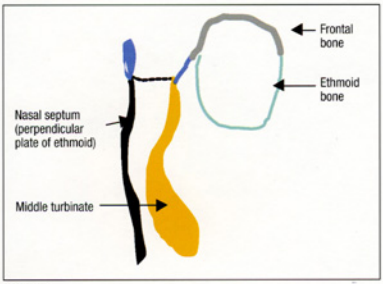

Fig. 20
Ethmoid labyrinth (schematic depiction, coronal view).

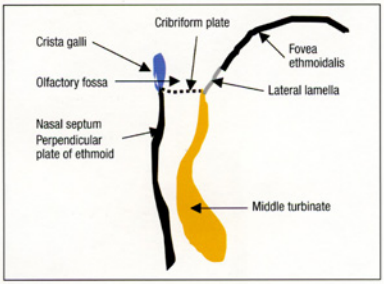

Fig. 21a
Roof of anterior ethmoid (schematic depiction, coronal view).

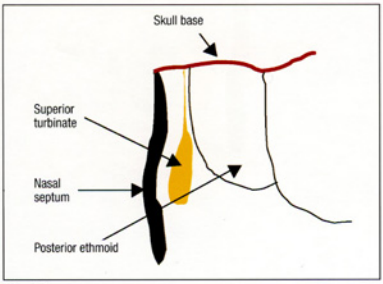

Fig. 21b
Roof of posterior ethmoid (schematic depiction, coronal view).

1.20 Ethmoid Labyrinth

The ethmoid labyrinth is composed of the frontal bone superiorly and ethmoid bone inferiorly, and contains the ethmoid air cells (**Fig. 20**).

1.21 Roof of the Ethmoids

The roof of the anterior ethmoids is composed of the frontal bone superiorly and laterally (this part is termed the fovea ethmoidalis) and the ethmoid bone inferiorly and medially (this part is termed lateral lamella of the cribriform plate). Part of the frontal bone, the fovea ethmoidalis is a thick bone (0.5 mm on average), whereas the lateral lamella is a rather thin (0.2 mm on average) part of the ethmoid bone. It should be noted that the dura of the anterior cranial fossa is relatively thin and adheres to the skull base. The roof of the anterior ethmoid has a stepladder-like appearance, whereas the roof of the posterior ethmoid is flat (**Figs. 21 a, b**).

1.22 Lateral Lamella

The lateral lamella is thinnest at the location of the anterior ethmoid arterial passage, averaging 0.05 mm (i.e. 1/10 of the thickness of the fovea ethmoidalis), which is why this is the most common location for iatrogenic CSF leakage (**Fig. 21a**).

1.23 Cribriform Plate

The cribriform plate is perforated by the olfactory nerve fibers. The structure is attached to the crista galli and the perpendicular plate of the ethmoid bone medially, and to the neck of the middle turbinate and the lateral lamella laterally (**Fig. 21 a**).

1.24 Olfactory Fossa

The olfactory fossa is located between the crista galli medially, cribriform plate inferiorly, and the lateral lamella laterally. The olfactory bulb is located here. The structure may be deep or shallow, depending on the length of the lateral lamella (**Figs. 24a, b, c**), a factor which also determines the difference in level between the cribriform plate and fovea ethmoidalis (ranging from 1–16 mm) (**Figs. 24-d**). The stepladder appearance of the anterior ethmoid roof, as defined by computed tomography, should always be born in mind during endoscopic sinus surgery, especially in contrast to the roof of the posterior ethmoid, which is flat and consists of frontal bone.

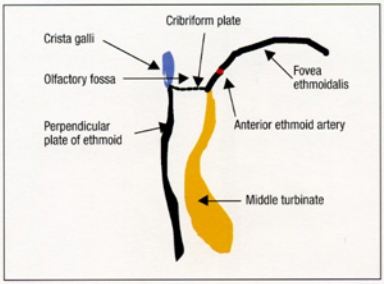

Fig. 24a
Shallow olfactory fossa (1-3 mm) due to the absence of a lateral lamella.

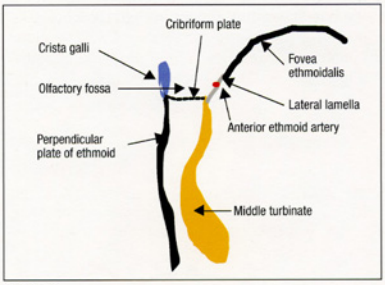

Fig. 24b
Olfactory fossa of average size (4-7 mm).

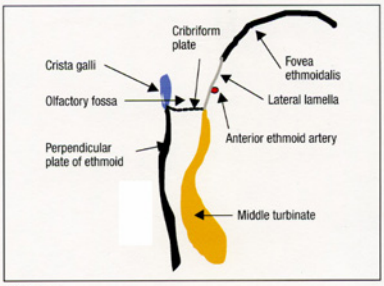

Fig. 24c
Deep olfactory fossa (8–16 mm).

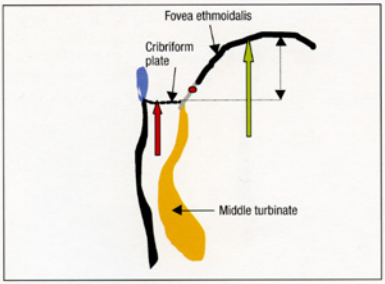

Fig. 24d
The roof of the ethmoid (green arrow) is usually situated at a higher level than the cribriform plate (red arrow) (ranging from 1-16 mm) (schematic depiction, coronal view).

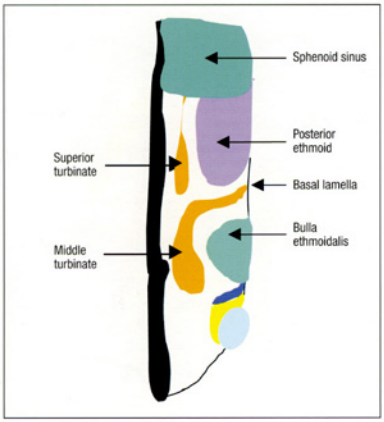

Fig. 25a
Left posterior ethmoids (schematic depiction, axial view).

1.25 Posterior Ethmoid Cells

The posterior ethmoid cells are larger in size and fewer in number than the anterior ethmoid cells. Posterior ethmoid cells have the following anatomical relationships:

- Anteriorly: the basal lamella (middle third of the middle turbinate) separates the posterior ethmoid cells from their anterior counterparts;
- Posteriorly: the anterior wall of the sphenoid sinus separates the posterior ethmoid cells from the sphenoid sinus;
- Laterally: the lamina papyracea separates the posterior ethmoid cells from the orbit;
- Medially: superior meatus and superior turbinate (**Fig. 25a**);
- Superiorly: the flat fovea ethmoidalis separates the posterior ethmoid cells from the anterior cranial fossa;
- Inferiorly: posterior part of the middle turbinate (**Fig. 25b**).

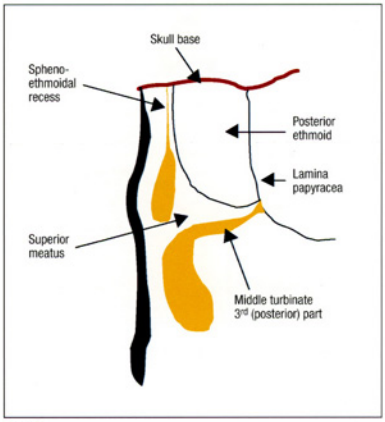

Fig. 25b
Left posterior ethmoids (schematic depiction, coronal view).

The posterior ethmoid cells are often found to be the cause of potential complications during endoscopic sinonasal surgery (orbital, cranial and/or bleeding) resulting from the following:

- the optic nerve is too close to the posterior ethmoid air cells.
- the medial rectus muscle is closer to the posterior ethmoid than to the anterior ethmoid, orbital fat being thinner here (**Fig. 25c**).
- the posterior ethmoid artery is located in the roof of the posterior ethmoid sinus just anterior to the anterior wall of the sphenoid sinus (**Fig. 25d**).
- the sphenoid sinus is located behind and below the posterior ethmoid air cells (**Fig. 25e**).

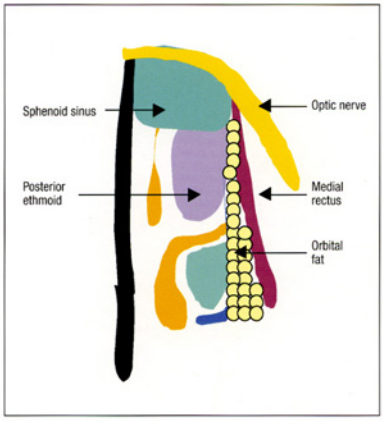

Fig. 25c
Left posterior ethmoids (schematic depiction, axial view).

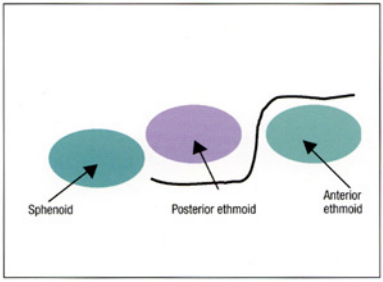

Fig. 25e
Posterior ethmoid is in a higher position than the sphenoid sinus (schematic depiction, sagittal plane).

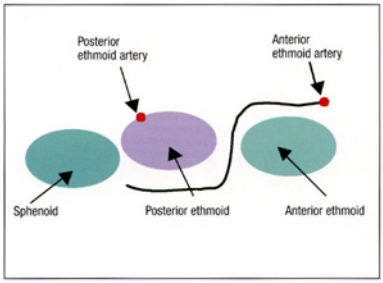

Fig. 25d
Anterior and posterior ethmoid arteries (schematic depiction, sagittal plane).

1.26 Sphenoethmoidal Cell (Onodi Cell)

The Onodi cell is a lateral and superior extension of the posterior ethmoids (relative to the position of the sphenoid sinus) and arises from hyperpneumatization of the posterior ethmoid air cells. This structure is very often closely related to the optic nerve and/or internal carotid artery (**Figs. 26a, b, c, d**).

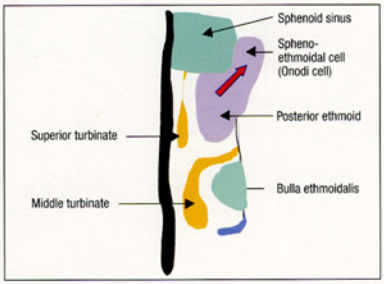

Fig. 26a
Left sphenoethmoidal cell (Onodi cell) (schematic depiction, axial view). Red arrow indicates lateral and posterior hyperpneumatization of the posterior ethmoids.

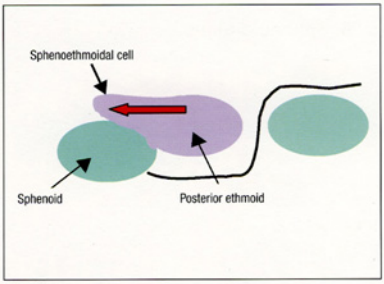

Fig. 26b
Left sphenoethmoidal cell (Onodi cell) (schematic depiction, sagittal view). Red arrow indicates superior and posterior hyperpneumatization of the posterior ethmoids.

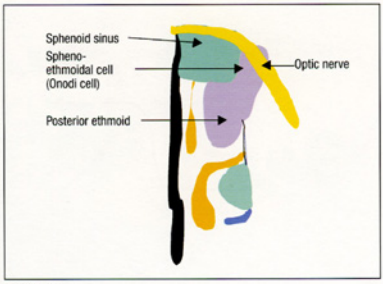

Fig. 26c
Left sphenoethmoidal cell (Onodi cell) and optic nerve (schematic depiction, axial view).

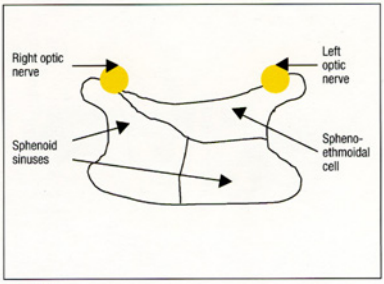

Fig. 26d
Left sphenoethmoidal cell (Onodi cell) and optic nerve (schematic depiction, coronal view).

1.27 Sphenopalatine Foramen

The sphenopalatine foramen is located behind the posterior end of the middle turbinate and is formed by the following structures:

- Superiorly: sphenoid bone.
- Posteriorly: sphenoid process of the palatine bone.
- Anteriorly: ethmoid process of the palatine bone.
- Inferiorly: palatine bone.

The sphenopalatine foramen leads to the pterygopalatine fossa, which forms the exit of the nasal neurovascular bundle (**Fig. 27**).

1.28 Sphenoid Sinus

Three different types of sphenoid sinus are classified on the basis of pneumatization, namely conchal, presellar, and sellar types. The spatial relationship of the structure is as follows:

- Superiorly: anterior cranial fossa;
- Anteriorly: spheno-ethmoid recess, superior turbinate, and posterior ethmoids (**Fig. 28b**);
- Medially: sphenoid septum or septae which may differ in location, direction, number, thickness, and attachment to other structures;
- Inferiorly: nasopharynx;
- Posteriorly: basi-sphenoid, sella, posterior cranial fossa;
- Laterally: middle cranial fossa and cavernous sinus (**Fig. 28c**).

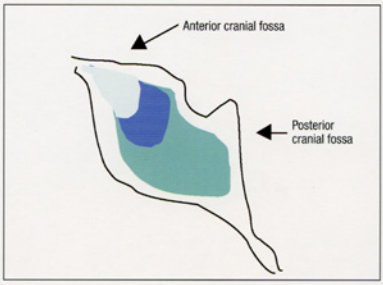

Fig. 28a
The three types of the sphenoid sinus: conchal, presellar and sellar (schematic depiction, sagittal view).

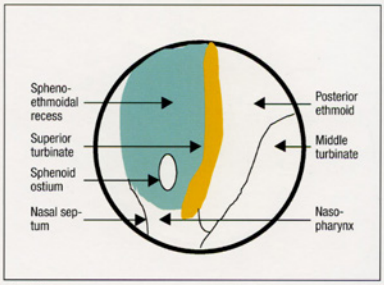

Fig. 28b
Left sphenoid sinus anterior and inferior relationships (endoscopic view).

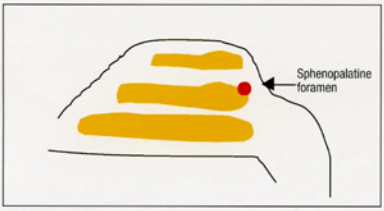

Fig. 27
Right sphenopalatine foramen (schematic depiction, sagittal view).

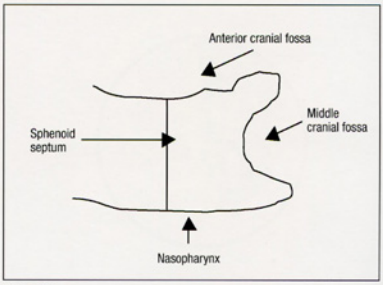

Fig. 28c
Left sphenoid sinus (schematic depiction, coronal view).

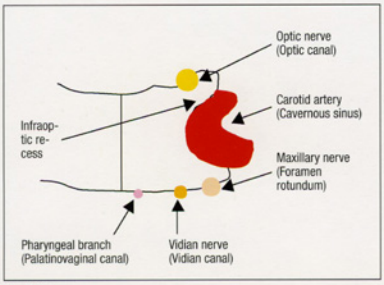

Fig. 29a
Neurovascular relationships of the left sphenoid sinus (schematic depiction, coronal view).

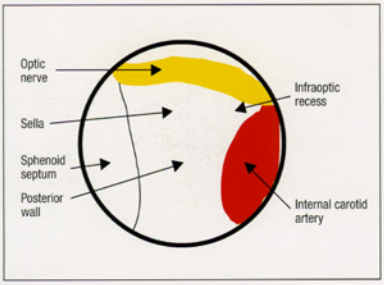

29b
The left sphenoid sinus (endoscopic view).

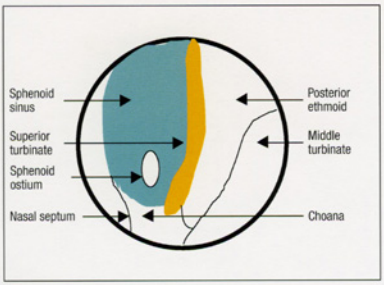

Fig. 30
Left sphenoid ostium (endoscopic view).

1.29 Neurovascular Relationships of the Sphenoid Sinus

The sphenoid sinus is situated in close structural proximity to the following structures:

- Optic nerve inside the nerve canal (6 % incidence of bony dehiscence).
- Internal carotid artery inside the cavernous sinus (20% incidence of bony dehiscence).
- Maxillary nerve in the foramen rotundum.
- Vidian nerve inside the pterygoid canal.

The infraoptic recess is situated between the optic nerve and the internal carotid artery. Its size and depth depend on the degree of pneumatization of the anterior clenoid process (**Figs. 29a, b**).

1.30 The Sphenoid Sinus Ostium

The sphenoid sinus ostium opens into the spheno-ethmoidal recess. It is located just medial to the posterior end of the superior turbinate and can be identified by tracing the roof of the nasopharynx, forming the floor of the sphenoid sinus, through the choana to the anterior wall of the sphenoid. The structure is located between the nasal septum and the inferior part of the superior turbinate (**Fig. 30**).

1.31 Nasopharynx

The examiner should identify the following structures in the nasopharynx:

- Ipsilateral Eustachian tube.
- Ipsilateral fossa of Rosenmüller.
- Roof of the nasopharynx.
- Posterior wall of the nasopharynx.
- Contralateral fossa of Rosenmüller.
- Contralateral Eustachian tube (**Fig. 31**).

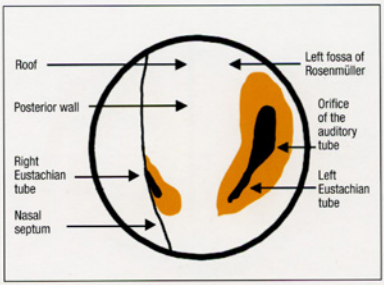

Fig. 31
View of the nasopharynx through the left nasal cavity (endoscopic view).

1.32 Nasal Choana

The following structures demarcate the posterior nasal aperture (the nasal choana):

- Inferiorly: nasal floor.
- Medially: nasal septum.
- Superiorly: sphenoid sinus.
- Laterally: medial pterygoid plate (**Fig. 32**).

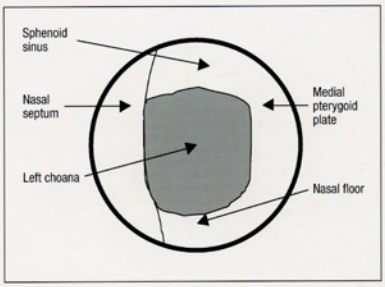

Fig. 32
Boundaries of the left choana (endoscopic view).

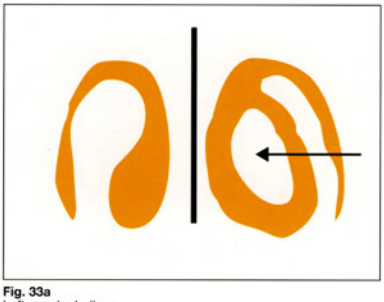

Fig. 33a
Left concha bullosa.

1.33 Anatomic Variations

The examiner must be aware that a large number of anatomic variations is encountered in this area, most commonly:

- Concha bullosa: pneumatized head of the middle turbinate (**Fig. 33a**).
- Interlamellar cell: pneumatized vertical lamella of the middle turbinate (**Fig. 33b**).
- Paradoxically bent middle turbinate: reversed C-shape of the middle turbinate (**Fig. 33c**).
- Medially bent uncinate process (**Fig. 33d**).

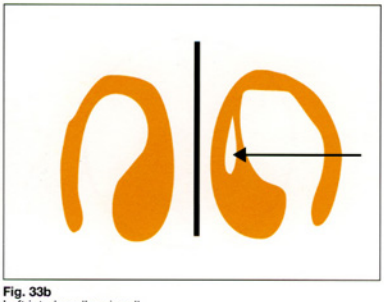

Fig. 33b
Left interlamellar air cell.

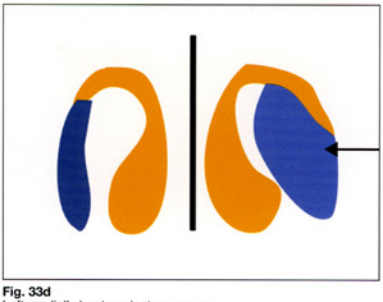

Fig. 33d
Left medially bent uncinate process.

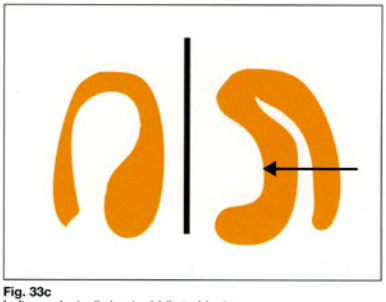

Fig. 33c
Left paradoxically bent middle turbinate.

- Large bulla ethmoidalis (**Fig. 33e**)
- Unpneumatized bulla ethmoidalis: the bulla ethmoidalis is represented by a bony projection from the lamina papyracea termed torus lateralis (**Fig. 33f**).
- Infraorbital ethmoid cell (Haller cell): this is an ethmoid air cell positioned inferior and lateral to the ethmoid bulla and closely related to the maxillary sinus ostium and the infundibulum (**Fig. 33g**).
- Hypoplastic or aplastic maxillary sinus: in this variation, the maxillary sinus is smaller or nonexistent, the adjacent maxillary bone is thicker, the uncinate process is hypoplastic and laterally dislocated and the ethmoid infundibulum is accordingly atelectatic (**Fig. 33h**).

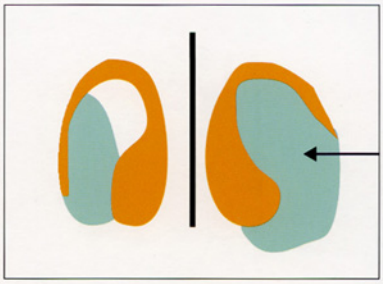

Fig. 33e
Left large bulla ethmoidalis.



Fig. 33f
Left unpneumatized bulla ethmoidalis (torus lateralis).

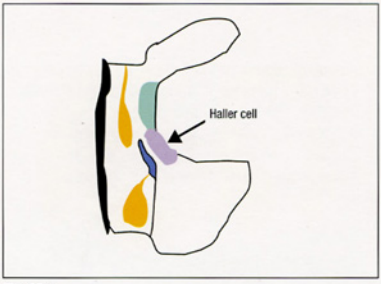

Fig. 33g
Left Haller cell (schematic depiction, coronal view).

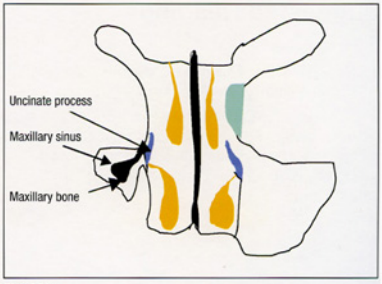

Fig. 33h
Right hypoplastic maxillary sinus (schematic depiction, coronal view).

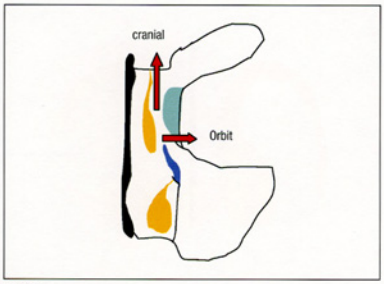

Fig. 34
Possible orbital and intra-cranial complications of endoscopic sinonasal surgery (schematic depiction, coronal view).

Conclusion

A detailed and thorough understanding of the anatomy of the lateral nasal wall, ostiomeatal complex and anterior skull base is mandatory for conducting **safe** and **effective** surgery. Orbital and intracranial **complications** may result from any injury or damage inflicted on the sinonasal framework laterally and/or superiorly, a factor which should always be treated with respect during endoscopic sinus surgery (**Fig. 34**).

Suggested Reading

1 MESSERKLINGER, W: *Endoscopy of the Nose.* Urban & Schwarzenberg, 1978.

2 STAMMBERGER, H; HAWKE, M: *Essentials of Functional Endoscopic Sinus Surgery.* Mosby: Stamathis, G. (Publ.); Hurley, R. (Ed.), 1993.

3 HOSEMANN, W G; WEBER, R K; KEERL, R E; LUND, V J: *Minimally Invasive Endonasal Sinus Surgery*. Thieme, 2000.

4 KENNEDY, D W; BOLGER, W B; ZINREICH, S J: *Diseases of the Sinuses. Diagnosis and Management.* B. C. Decker Inc., 2000.

Instrument Sets for Endoscopic Diagnosis and Surgery of the Lateral Nasal Wall, Ostiomeatal Complex and Anterior Skull Base

as recommended by Prof. Reda KAMEL, M.D.

Telescopes, Instruments and Accessories
Cold Light Fountains and Imaging Systems
for Video Documentation

Diagnostic Endoscopy Set

Recommended Set according to Prof. Reda KAMEL, M. D.



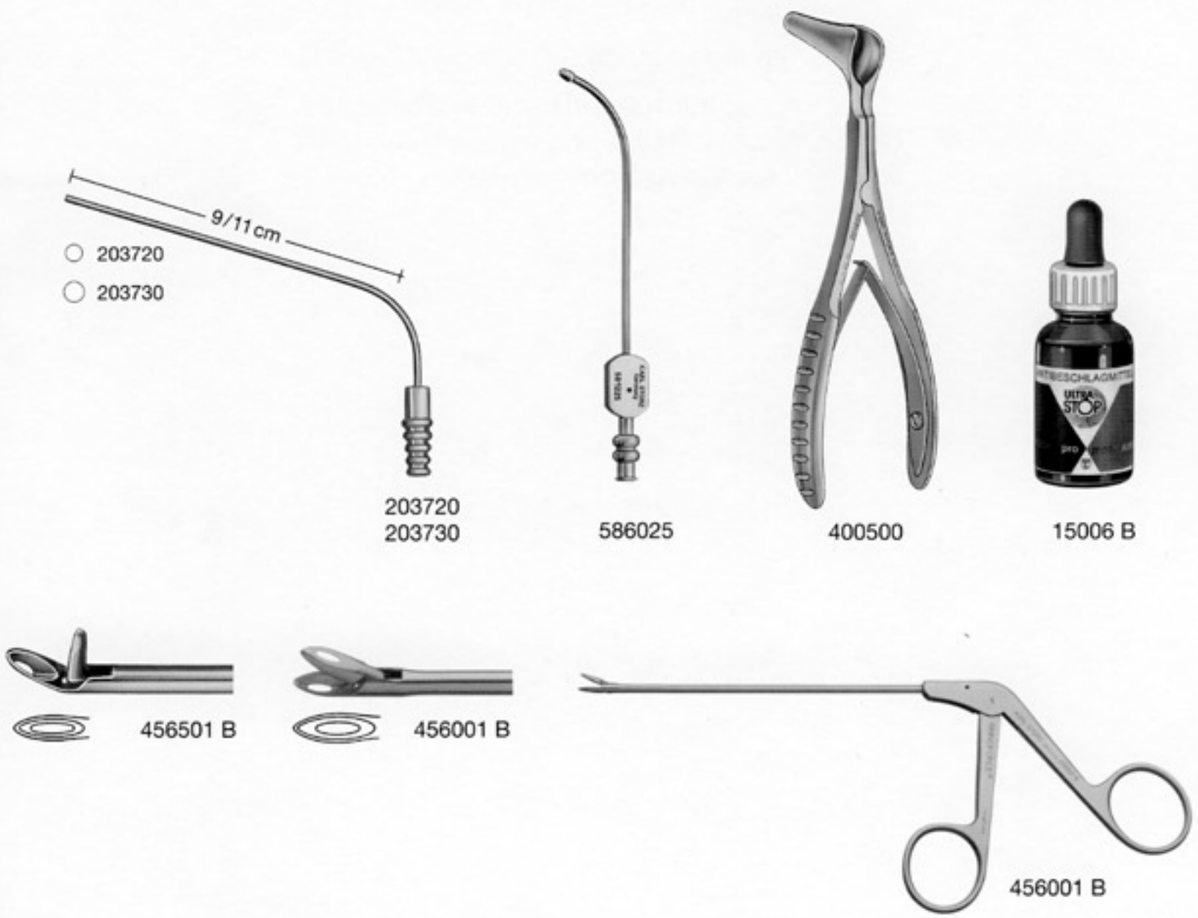

Diagnostic Endoscopy Set

Recommended Set according to Prof. Reda KAMEL, M. D.

7230 BWA	1	HOPKINS® **Wide-Angle Forward-Oblique Telescope** 30°, enlarged view, diameter 4 mm, length 18 cm, **autoclavable.** Fiber optic light transmission incorporated, color code: red.
15006 B	1	"ULTRA-STOP" **Antifog Solution,** 25 ml pipette bottle.
723750 B	1	**Protection Tube** for 18 cm HOPKINS® telescopes.
400500	1	HARTMANN **Nasal Speculum,** for adults, length 13 cm.
430300	1	LUBET-BARBON **Nasal Dressing Forceps,** working length 10.5 cm.
456001 B	1	RHINOFORCE® BLAKESLEY **Nasal Forceps,** straight, working length 13 cm, size 1.
456501 B	1	RHINOFORCE® STRUEMPEL-VOSS **Nasal Forceps,** 45° upturned, size 1.
203720	1	**Suction Tube,** cylindrical, LUER, working length 9 cm, O.D. 2 mm.
203730	1	**Suction Tube,** cylindrical, LUER, working length 11 cm, O.D. 3 mm.
586025	1	v. EICKEN **Antrum Cannula,** long curved, LUER-lock, length 12.5 cm, O.D. 2.5 mm.

Optional Telescope for Diagnosis in Children

7219 BA	1	HOPKINS® **Forward-Oblique Telescope** 30°, diameter 2.7 mm, length 18 cm, **autoclavable.** Fiber optic light transmission incorporated, color code: red.
723750 B	1	**Protection Tube** for 18 cm HOPKINS® telescopes.

Endoscopic Sinonasal Surgery Set

Recommended Set according to Prof. Reda KAMEL, M. D.

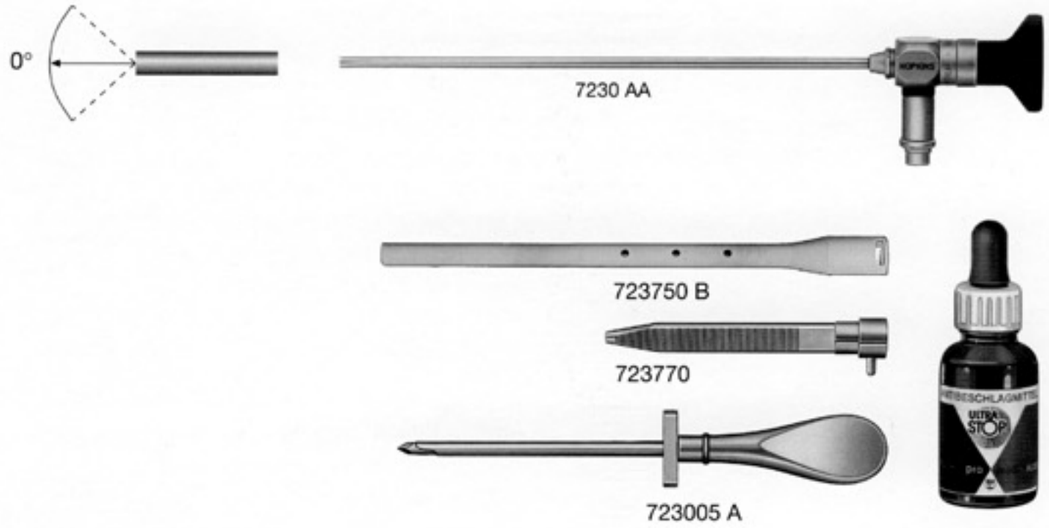

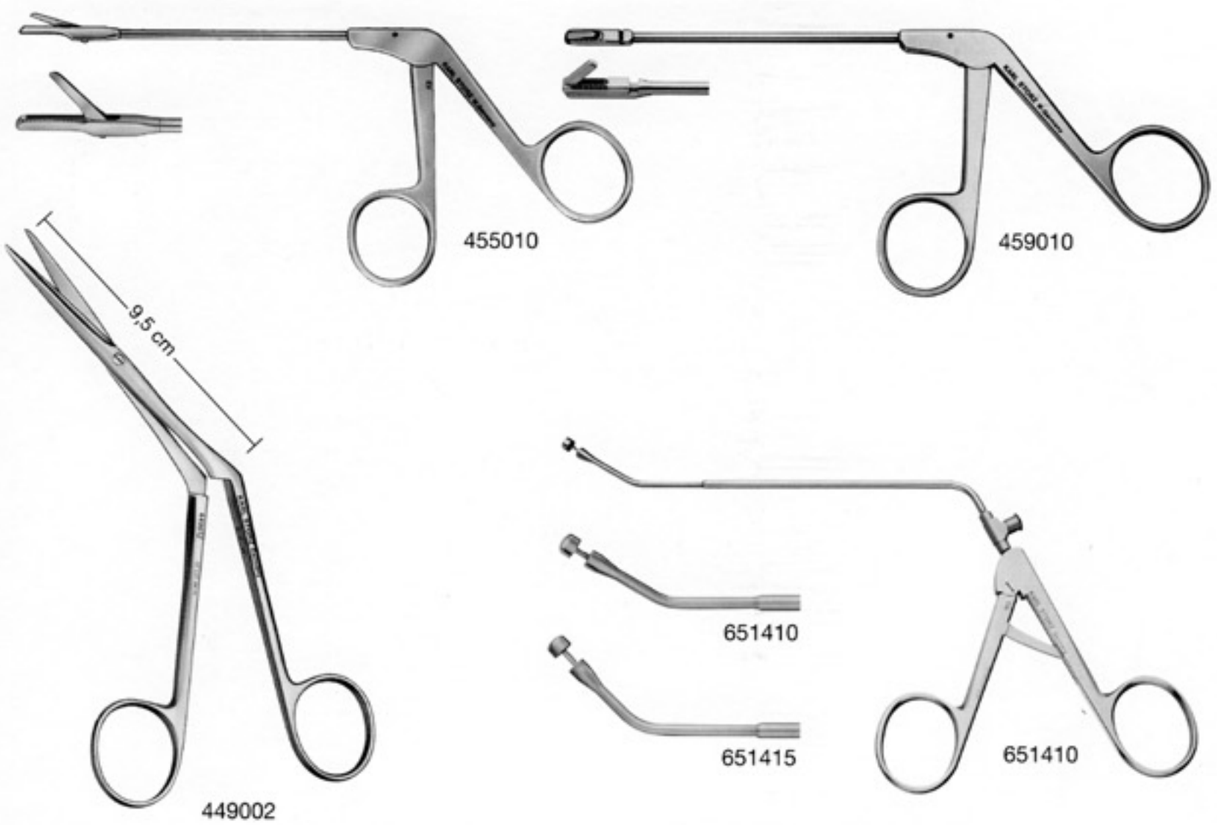

Endoscopic Sinonasal Surgery Set

Recommended Set according to Prof. Reda KAMEL, M. D.

7230 AA	1	HOPKINS® **Straight Forward Telescope** 0°, enlarged view, diameter 4 mm, length 18 cm, **autoclavable.** Fiber optic light transmission incorporated. Color code: green.
723750 B	1	**Protection Tube** for 18 cm HOPKINS® telescopes.
723770	1	STAMMBERGER **Telescope Handle,** length 11 cm, flat, for use with 18 cm HOPKINS® telescopes.
810506	1	**Septum Needle,** angular, LUER-lock.
628001	1	**Sickle Knife,** 19 cm, pointed.
474000	1	FREER **Elevator,** double-ended, length 20 cm.
456001 B	1	RHINOFORCE® BLAKESLEY **Nasal Forceps,** straight, working length 13 cm, size 1.
456501 B	1	RHINOFORCE® STRUEMPEL-VOSS **Nasal Forceps,** 45° upturned, size 1.
723005 A	1	**Trocar and Cannula** for sinoscopy, O. D. 5 mm, length of cannula 8.5 cm, fenestrated beak, for use with 4 mm HOPKINS® telescopes.
629820	1	**Probe,** double-ended, maxillary sinus ostium seeker, length 19 cm, ball sizes: diameter 1.2 and 2.0 mm.
459010	1	RHINOFORCE® STAMMBERGER **Antrum Punch,** working length 10 cm, upside backward cutting.
651410	1	KAMEL **Middle Meatal Antrostomy Punch,** circular cutting, punch head diameter 4.5 mm, 30° upturned, working length 13 cm.
651415	1	**Same,** 45° upturned.
457712	1	KAMEL **Nasal Forceps,** 45° upturned, cupped jaws 20 mm x 4 mm, working length 11 cm.
455010	1	RHINOFORCE® STRUYCKEN **Nasal Cutting Forceps,** working length 13 cm.
449002	1	HEYMANN **Nasal Scissors,** medium size, working length 9.5 cm.
203720	1	**Suction Tube,** cylindrical, LUER, working length 9 cm, O.D. 2 mm.
203730	1	**Same,** working length 11 cm, O.D. 3 mm.
586030	1	v. EICKEN **Antrum Cannula,** long curved, LUER-lock, length 12.5 cm, O.D. 3.0 mm.
586040	1	**Same,** O.D. 4.0 mm.
15006 B	1	"ULTRA-STOP" **Antifog Solution,** 25 ml pipette bottle.

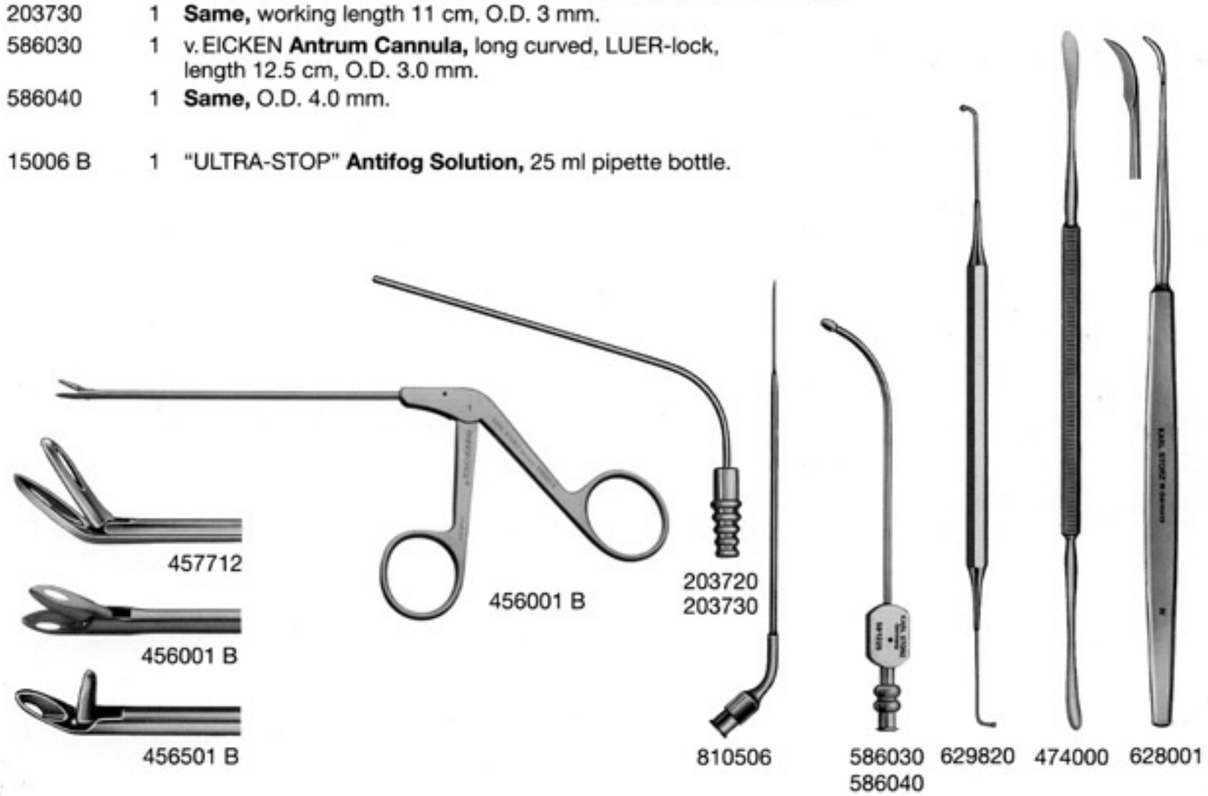

Additional Surgical Instruments and Accessories

Recommended Set according to Prof. Reda KAMEL, M. D.

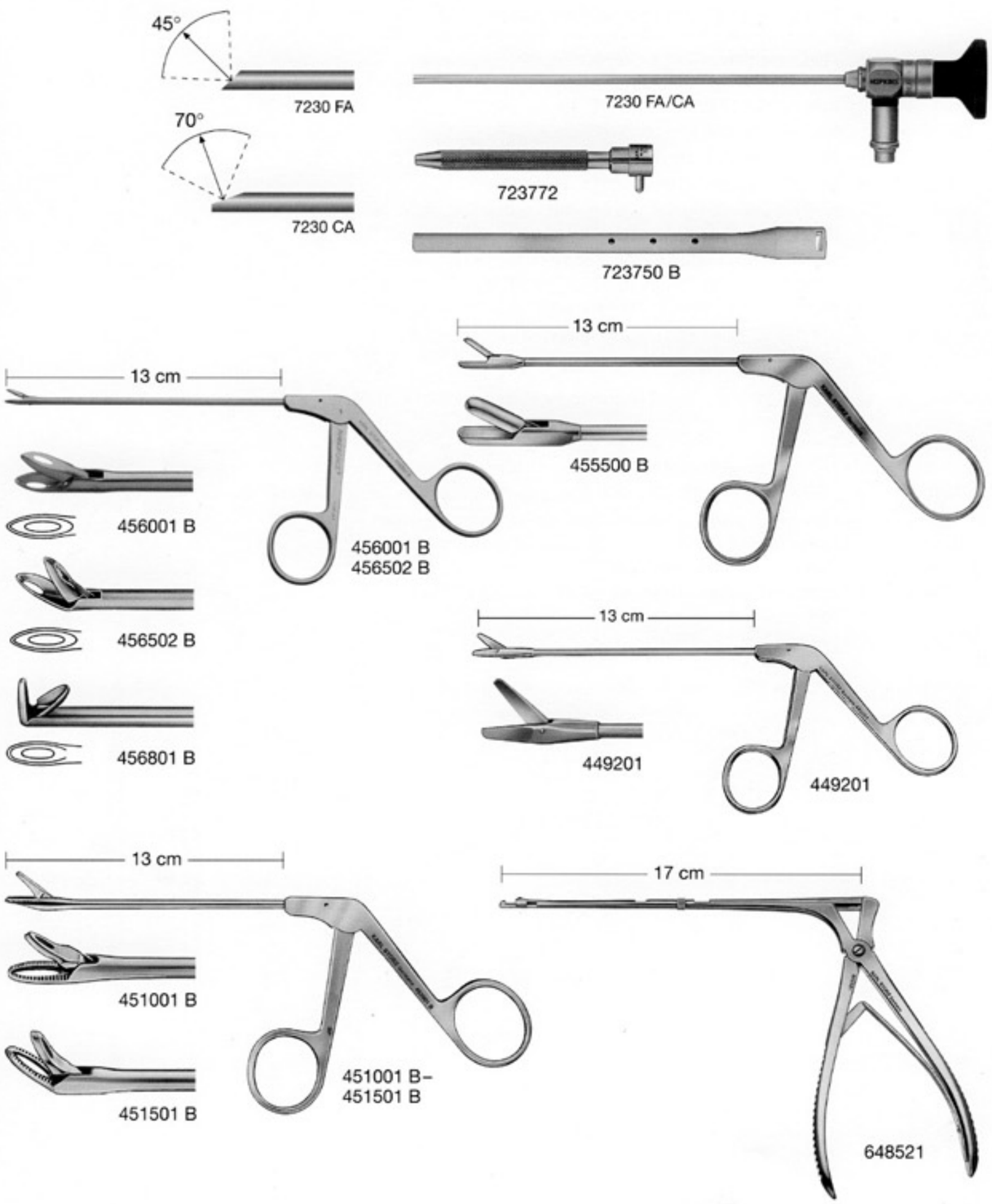

Additional Surgical Instruments and Accessories

Recommended Set according to Prof. Reda KAMEL, M. D.

7230 FA 1 HOPKINS® **Forward-Oblique Telescope** 45°, enlarged view, diameter 4 mm, length 18 cm, **autoclavable.** Fiber optic light transmission incorporated. Color code: black.

7230 CA 1 HOPKINS® **Lateral Telescope** 70°, diameter 4 mm, length 18 cm, **autoclavable.** Fiber optic light transmission incorporated. Color code: yellow.

723750 B 1 **Protection Tube** for 18 cm HOPKINS® telescopes.

723772 1 STAMMBERGER **Telescope Handle,** length 11 cm, round, for use with 18 cm HOPKINS® telescopes 30°, 45°, 70°, 90° and 120°.

451001 B 1 RHINOFORCE® BLAKESLEY **Nasal Forceps,** through-cutting, tissue-sparing, working length 13 cm, straight, size 1, 3.5 mm, wide.

451501 B 1 RHINOFORCE® BLAKESLEY **Nasal Forceps,** through-cutting, tissue-sparing, working length 13 cm, 45° upturned, size 1, 3.5 mm, wide.

455500 B 1 TAKAHASHI **Nasal Forceps,** straight, working length 11 cm.

456001 B 1 RHINOFORCE® BLAKESLEY **Nasal Forceps,** straight, working length 13 cm, size 1.

456502 B 1 RHINOFORCE® BLAKESLEY-WILDE **Nasal Forceps,** 45° upturned, working length 13 cm, size 0.

456801 B 1 RHINOFORCE® BLAKESLEY-WILDE **Nasal Forceps,** 90° upturned, working length 13 cm, size 1.

457711 1 KAMEL **Nasal Forceps,** 45° upturned, cupped jaws 12 mm x 4 mm, working length 11 cm.

651050 1 STAMMBERGER **Punch,** circular cutting, for sphenoid, ethmoid and choanal atresia, working length 18 cm, diameter 4.5 mm.

651415 1 KAMEL **Middle Meatal Antrostomy Punch,** circular cutting, punch head diameter 4.5 mm, 45° upturned, working length 13 cm.

648521 1 McKENTY **Sphenoid Punch,** through-cutting, reversible, size 1.8 mm x 2 mm, working length 17 cm.

449201 1 RHINOFORCE® **Nasal Scissors,** working length 13 cm, straight.

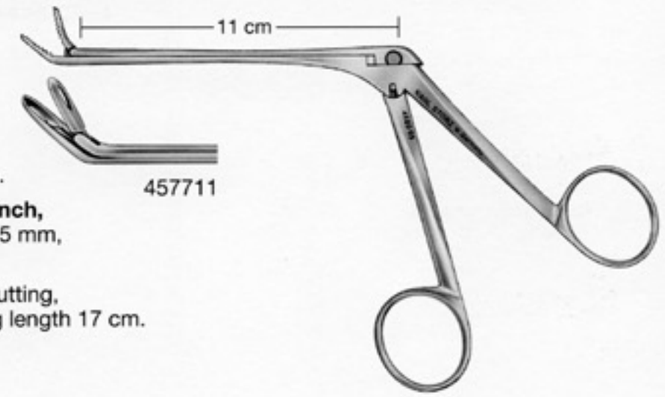

Set continued overleaf.

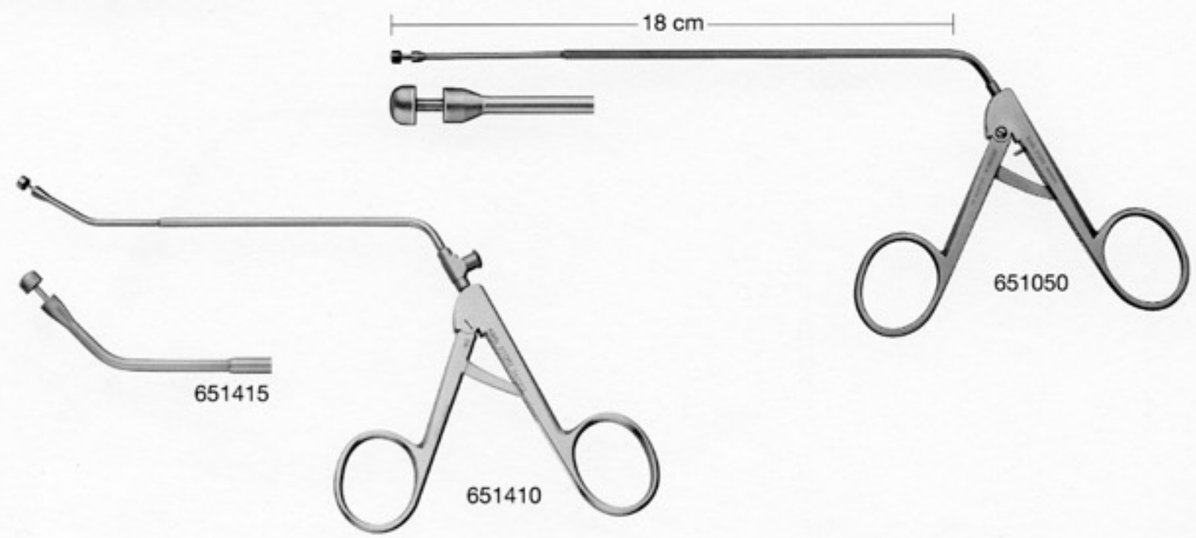

Additional Surgical Instruments and Accessories

Recommended Set according to Prof. Reda KAMEL, M. D

Continued from page 41.

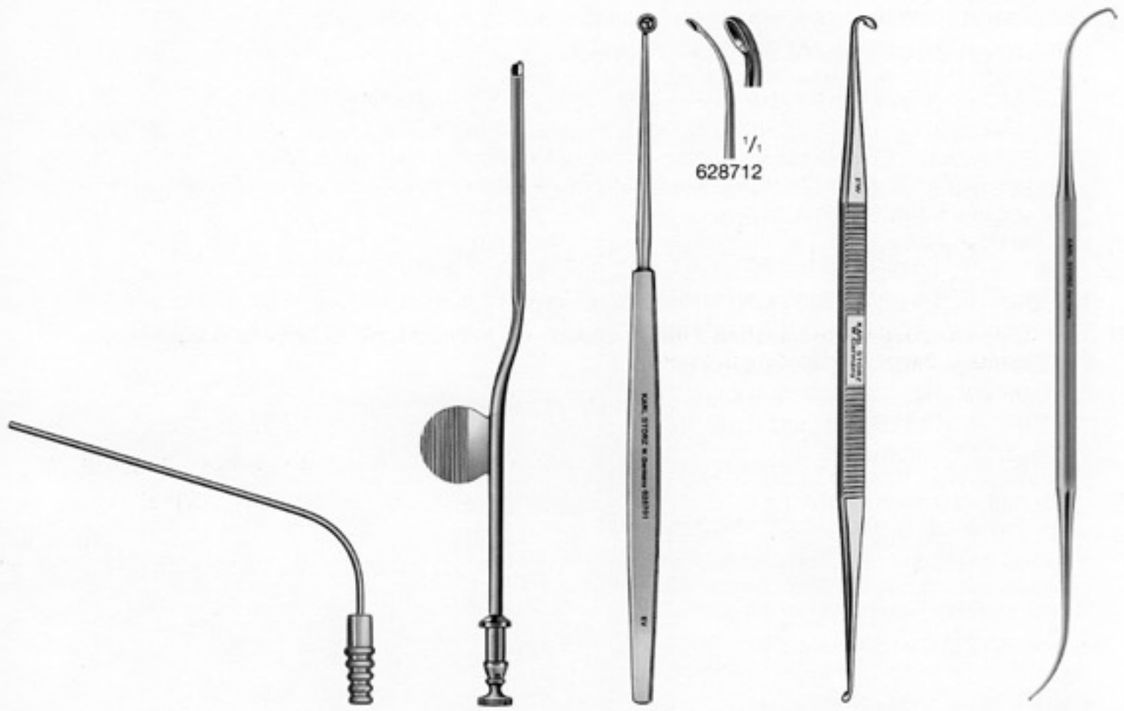



Additional Surgical Instruments and Accessories

Recommended Set according to Prof. Reda KAMEL, M. D.

203740	1	**Suction Tube,** cylindrical, LUER, working length 11 cm, O.D. 4 mm.
479800	1	**Suction Elevator** with stylet, length 19.5 cm.
628701	1	**Antrum Curette,** length 19 cm, round.
628712	1	KUHN-BOLGER **Frontal Sinus Curette,** small, oblong, forward cutting, length 19 cm, 55° curved.
628720	1	**Curette,** double-ended, oval, one side: short curved 45°, semi-sharp, diameter 2.2 mm, other side: long curved 90°, sharp, diameter 2.7 mm, length 19 cm.
629830	1	KUHN **Frontal Ostium Seeker,** double-ended, no. 6, both sides curved 77°, one tip straight, other reverse angle, length 22 cm.
634830	1	OGGEL **Probe,** reinforced on both sides.
634840	1	BOWMAN **Lachrymal Probe,** length 13 cm, set with 3 pcs., size 0000–000, 00–0, 1–2.
745900	1	WILDER **Dilator,** for lachrymal ducts, length 11 cm.
839310 N	1	**Unipolar Suction-Coagulation Tube,** insulated, with connector pin for unipolar coagulation, diameter 3 mm, working length 11 cm.
26005 M	1	**High Frequency Cord,** with **5 mm** plug for HF-electrosurgical generator, models KARL STORZ and Erbe.
843219	1	**Bipolar Coagulating Forceps,** with suction channel, nasal, blunt, insulated, straight, length 19 cm.
847000 E	1	**High Frequency Cord,** for KARL STORZ bipolar instruments, for use with AUTOCON® 50, AUTOCON® 200, AUTOCON® 350 and Erbe coagulator.

252479 **INTRA-Handpiece,** angled, **extra-long,** length 18 cm, for use with straight shaft burrs 12.5 cm, slender sheath, transmission 1:1 (40.000 rpm).

280052 **Universal Spray,** combination cleaner and lubricant for INTRA-handpieces, package of 6 sprayers 280052 B and spray diffuser 280052 C

261010 L **Tungsten Carbide Shaft Burrs,** length 12.5 cm, diameter 1.0 mm.

261018 L **Tungsten Carbide Shaft Burrs,** length 12.5 cm, diameter 1.8 mm.

261031 L **Tungsten Carbide Shaft Burrs,** length 12.5 cm, diameter 3.1 mm.

261040 L **Tungsten Carbide Shaft Burrs,** length 12.5 cm, diameter 4.0 mm.

262010 L **Diamond Shaft Burrs,** length 12.5 cm, diameter 1.0 mm.

262018 L **Diamond Shaft Burrs,** length 12.5 cm, diameter 1.8 mm.

262031 L **Diamond Shaft Burrs,** length 12.5 cm, diameter 3.1 mm.

262040 L **Diamond Shaft Burrs,** length 12.5 cm, diameter 4.0 mm.

KARL STORZ UNIDRIVE® ENT for use with **INTRA Handpiece** 252479 see pages 46–47.

KARL STORZ CLEARVISION™ System

for intra-operative rinsing of the telescope lens



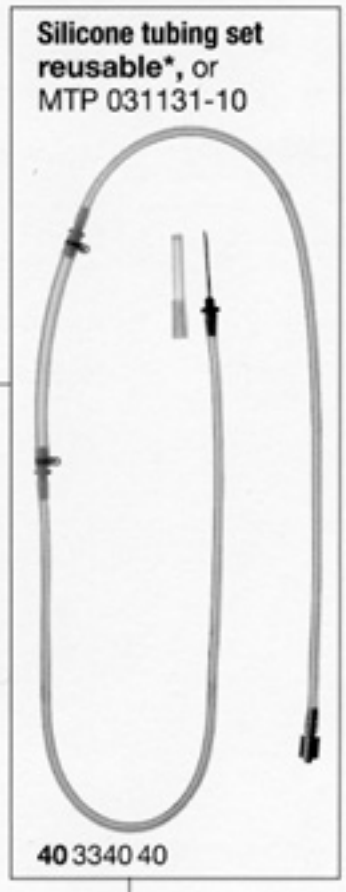

40 3340 01 **KARL STORZ CLEARVISION™,**
irrigation pump for intra-operative
rinsing of the telescope lens,
power supply: 100–240 VAC, 50–60 Hz,
consisting of:
40 3340 20 **CLEARVISION™**
400 A **Mains Cord.**
20 0101 30 **One-pedal Footswitch**
40 3340 40 **Silicone Tubing Set.**



)*Optional Accessories:

MTP 031129-10 Disposable irrigation tube for CLEARVISION™,
package of 10

Submit your order to:
mtp, medical technical promotion gmbh,
p.o. box 4529, D-78510 Tuttlingen, Germany

KARL STORZ CLEARVISION™ System

Compatibility Matrix of Irrigation Sheaths and HOPKINS® Telescopes

	Irrigation Sheath, proximally reinforced for use with holder 28172 SL			**Compatible HOPKINS® Telescopes**			
	Part No.	Outer diameter	Working length	Part No.	Direction of view	Outer diameter	Working length
	28164 CAA	3.8 mm	15 cm	7219 AA	0°	2.7 mm	18 cm
	28164 CBA	5.0 mm	14 cm	7230 AA	0°	4.0 mm	18 cm
	28164 CAF	3.8 mm	15 cm	7219 FA	45°	2.7 mm	18 cm
	28164 CBF	5.0 mm	14 cm	7230 FA	45°	4.0 mm	18 cm
	28164 CAC	3.8 mm	15 cm	7219 CA	70°	2.7 mm	18 cm
	28164 CBC	5.0 mm	14 cm	7230 CA	70°	4.0 mm	18 cm

UNIDRIVE® ENT

System Configurations recommended by KARL STORZ

207116 20-1

407116 01-1 **UNIDRIVE® ENT**
consisting of:

- **20**7116 20-1 **UNIDRIVE® ENT with KARL STORZ Communication Bus System SCB®**, 100 – 120, 230 – 240 VAC, 50/60 Hz
- 400 A **Mains Cord**
- **20**0126 30 **Two-Pedal Footswitch,** two-stage, with proportional function
- **20**7116 40 **Silicone Tubing Set,** for irrigation, sterilizable
- **20**7116 21 **Clip-Set,** for use with tubing set **20**7116 40
- **20**0901 70 **SCB Connecting Cable,** length 100 cm

Optional Accessories:

- **20**7110 32 **High Performance EC Micro Motor**
- **20**7110 72 **Connecting Cable,** to connect EC motor **20**7110 32 to control unit
- **40**7110 35 **Micro Shaver Handpiece, straight,** with integrated EC micro motor and connecting cable for use with UNIDRIVE® ENT
- **40**7110 39 STAMMBERGER **Paranasal Sinus Shaver Handpiece,** 90° angle, with EC micro motor
  consisting of:
  - **40**7110 37 **Housing of the Paranasal Sinus Shaver Handpiece**
  - **40**7110 38 **Motor of the Paranasal Sinus Shaver Handpiece,** without connecting cable **20**7110 70
- **20**7110 70 **Connecting Cable,** to connect UNIDRIVE® ENT with STAMMBERGER Paranasal Sinus Shaver Handpiece **40**7110 39, 90° angle
- **40**7110 40 STAMMBERGER-CASTELNUOVO **DrillCut-X Shaver Handpiece,** for use with UNIDRIVE® ENT
- 280052 B **Universal Sprayer,** 0.5 l bottle, for use with 280052 C, – HAZARDOUS GOODS – UN 1950
- 280052 C **Spray Diffuser,** for use with 280052 B
- mtp* **Set of Tubes,** for single patient use

*** This product is marketed by mtp.**
For additional information, please apply to:

mtp medical technical promotion gmbh,
Postfach 4529, 78510 Tuttlingen, Germany

UNIDRIVE® ENT

System Components



Sinus Shaver Handpieces

Special Features:

- **Strong and reliable suction**
- **Smooth operation**
- **Cuts the tissue without ripping; therefore less bleeding**
- **360° rotating shaver blade**
- **Graduated outer sheath**
- **All handpieces are fully autoclavable**
- **For use with both straight or curved paranasal shaver blades**

Paranasal Sinus Shaver Handpiece 40 711039

- **Ergonomically formed, 90° angled handpiece**
- **Oscillating operation mode. Max. drilling speed 7,000 rpm A rotation speed of 3,000 rpm is recommended as this provides the most efficient suction.**
- **Cooling vents prevent motor from overheating**
- **Straightforward, central irrigation channel enables optimal suction of blood and tissue**
- **Suction function can be switched off at the handpiece under sterile conditions**
- **Special lubrication holes ease maintenance (lubrication)**
- **Easy cleaning and maintenance. The housing (upper part 40** 711037**) is machine-washable. LUER-Lock connection enables additional machine cleaning. Meets highest hygienic standards.**
- **The device can be dismantled easily into two pieces at the touch of a button: housing and motor unit**

40 711039 STAMMBERGER **Paranasal Sinus Shaver Handpiece,** 90° angled, with EC motor

consisting of:

40 711037 **Paranasal Sinus Shaver Handpiece Housing**

40 711038 **Paranasal Sinus Shaver Handpiece Motor,** without connecting cable **20** 711070

20 711070 **Connecting Cable,** to connect UNIDRIVE® ENT with STAMMBERGER Paranasal Sinus Shaver Handpiece **40** 711039, 90° angle

Micro Shaver Handpiece 40 711035

- **Ergonomically formed, straight handpiece**
- **Oscillating operation mode, max. drilling speed 3,000 rpm**
- **Powerful motor enables continuous operation**
- **Extremely light construction**
- **Fully immersible and machine-washable**

40 711035 **Micro Shaver Handpiece, straight,** with integrated EC micro motor and connecting cable for use with UNIDRIVE® ENT

STAMMBERGER-CASTELNUOVO **DrillCut-X Shaver Handpiece**

DrillCut-X Handpiece 40 7110 40

- **Ergonomically formed, angled handpiece, optimally fits the hand**
- **Oscillating operation mode for shave blades, max. 7,000 rpm**
- **Rotating mode for sinus shavers, max. 12,000 rpm**
  Drilling speed of 3,000 rpm is recommended as this provides the most efficient suction.
- **Absolutely straight suction and irrigation channels**
- **With integrated irrigation – removed material is therefore more fluid to prevent blockages**
- **Very powerful motor, also suitable for removing harder material**
- **Very quiet operation, low vibration**
- **Special lubrication holes for easy maintenance**
- **With LOCK for positioning shaver blades and sinus shavers, if required**
- **Fully immersible and machine-washable**

40 7110 40 STAMMBERGER-CASTELNUOVO **DrillCut-X Shaver Handpiece,** for use with UNIDRIVE® ENT

Shaver Blades, straight

for Paranasal Sinuses and Skull Base Surgery

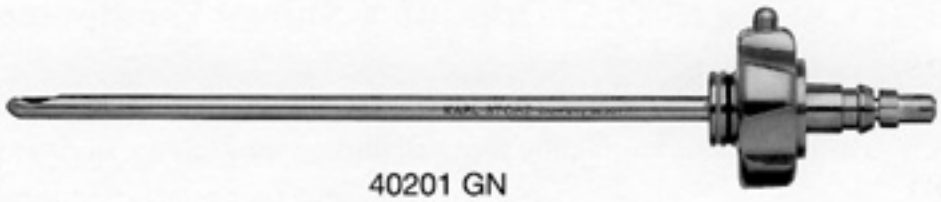

40201 GN

Detailed View	for use with Paranasal Sinus Shaver Handpiece **40** 711039 and Micro Shaver Handpiece **40** 711035		for use with DrillCut-X Handpiece, with longer blade and integrated irrigation, **40** 711040		**Suction Shaver Blade**, length 12 cm
	sterilizable	for single use, sterile, package of 5	sterilizable	for single use, sterile, package of 5	
	40201 KN	40301 KN	41201 KN	41301 KN	serrated cutting edge, diameter 4 mm, color code: blue-red
	40201 KK	40301 KK	41201 KK	41301 KK	double serrated cutting edge, diameter 4 mm, color code: blue-yellow
	40201 GN	40301 GN	41201 GN	41301 GN	concave cutting edge, oval cutting window, diameter 4 mm, color code: blue-green
	40201 LN	40301 LN	41201 LN	41301 LN	concave cutting edge, rectangular cutting window, diameter 4 mm, color code: blue-black
	40201 SN	40301 SN	41201 SN	41301 SN	straight cutting edge, diameter 4 mm, color code: blue-blue
	40201 KSA	40301 KSA	41201 KSA	41301 KSA	serrated cutting edge, diameter 3 mm, color code: blue-red
	40201 KKSA	40301 KKSA	41201 KKSA	41301 KKSA	double serrated cutting edge, diameter 3 mm, color code: blue-yellow
	40201 LSA	40301 LSA	41201 LSA	41301 LSA	concave cutting edge, rectangular cutting window, diameter 3 mm, color code: blue-black

Shaver Blades, slightly curved

for Paranasal Sinuses and Skull Base Surgery

40202 KN

Detailed View	**for use with Paranasal Sinus Shaver Handpiece 40** 7110 39 and **Micro Shaver Handpiece 40** 7110 35	**for use with DrillCut-X Handpiece,** with longer blade and integrated irrigation, **40** 7110 40		**Suction Shaver Blade,** length 12 cm
	for single use, sterile, package of 5	sterilizable	for single use, sterile, package of 5	
	40302 KN	41202 KN	41302 KN	35° curve, cutting edge backwards, serrated, diameter 4 mm, color code: blue-red
	40304 KKF	41204 KKF	41304 KKF	40° curve, cutting edge forwards, double serrated, diameter 4 mm, color code: blue-yellow
	40304 KKB	41204 KKB	41304 KKB	40° curve, cutting edge backwards, double serrated, diameter 4 mm, color code: blue-yellow
	40304 KKFA	41204 KKFA	41304 KKFA	40° curve, cutting edge forwards, double serrated, diameter 3 mm, color code: blue-yellow
	40304 KKBA	41204 KKBA	41304 KKBA	40° curve, cutting edge backwards, double serrated, diameter 3 mm, color code: blue-yellow

Shaver Blades, strongly curved

for Paransal Sinuses and Skull Base Surgery

40203 KKF

Detailed View	for use with Paranasal Sinus Shaver Handpiece 40 711039 and Micro Shaver Handpiece 40 711035	for use with DrillCut-X Handpiece, with longer blade and integrated irrigation, 40 711040		Suction Shaver Blade, length 12 cm
	for single use, sterile, package of 5	sterilizable	for single use, sterile, package of 5	
	40303 KNF	41203 KNF	41303 KNF	65° curve, cutting edge forwards, serrated, diameter 4 mm, color code: blue-red
	40303 KNB	41203 KNB	41303 KNB	65° curve, cutting edge backwards, serated, diameter 4 mm, color code: blue-red
	40303 KKF	41203 KKF	41303 KKF	65° curve, cutting edge forwards, double serrated, diameter 4 mm, color code: blue-yellow
	40303 KKB	41203 KKB	41303 KKB	65° curve, cutting edge backwards, double serrated, diameter 4 mm, color code: blue-yellow
	40303 KKFA	41203 KKFA	41303 KKFA	65° curve, cutting edge forwards, double serrated, diameter 3 mm, color code: blue-yellow
	40303 KKBA	41203 KKBA	41303 KKBA	65° curve, cutting edge backwards, double serrated, diameter 3 mm, color code: blue-yellow
	40303 GNF	41203 GNF	41303 GNF	65° curve, cutting edge forwards, serrated, oval cutting window, diameter 4 mm, length 12 cm, color code: blue-green
	40303 GNB	41203 GNB	41303 GNB	65° curve, cutting edge backwards, serrated, oval cutting window, diameter 4 mm, color code: blue-green

Sinus Burrs

for Paranasal Sinuses and Skull Base Surgery

41305 DN

Detailed View	for use with **DrillCut-X Handpiece,** with longer blade and integrated irrigation, **40** 711 0 40 for single use, sterile, package of 5	**Sinus Burr,** length 12 cm
	41304 W	40° curve, oblong, burr diameter 3 mm, shaft diameter 4 mm, color code: red-blue
	41303 WN	55° curve, oblong, with protective sheath, burr diameter 3.6 mm, shaft diameter 4 mm, color code: red-blue
	41305 RN	15° curve, round drill with protective sheath, burr diameter 4 mm, shaft diameter 4 mm, color code: red-black
	41305 DN	15° curve, diamond head with protective sheath, burr diameter 3 mm, shaft diameter 4 mm color code: red-yellow
	41305 D	15° curve, diamond head, burr diameter 5 mm, shaft diameter 4 mm, color code: red-yellow
	41303 DT	70° curve, diamond head, burr diameter 3.6 mm, shaft diameter 4 mm, color code: red-yellow

Camera System IMAGE1™

Camera Control Unit

IMAGE1™ is the first truly digital endoscopic video camera. This video camera system instantly converts optical images to digital at the earliest possible site: the CCD sensing chip. This sensor delivers Digital First, a digital signal "through and through" for visibly improved imaging on all digital recording and display devices.

The advantages over other systems are obvious: Only IMAGE1™ offers the resolution and light sensitivity necessary for the highest digital image quality.

22 2000 20-102

22 2000 11U102 **IMAGE1™ Camera Control Unit,**
with integrated **KARL STORZ Communication Bus System SCB®;**
integrated digital Image Processing Module and SDI Module

consisting of:

22 2000 20-102	**IMAGE1™ Camera Control Unit,** with SDI module
400 A	**Mains Cord**
400 B	**Mains Cord,** US-version
20 2001 30U	**Keyboard,** US-version
2x **20** 2210 70	**Connecting Cable,** for controlling peripheral units, length 180 cm
3x 536 MK	**BNC/BNC Video Cable,** length 180 cm
547 S	**S-Video (Y/C) Connecting Cable,** length 180 cm
20 2032 70	**Special RGB Connecting Cable,** length 180 cm
20 0901 70	**SCB Connecting Cable,** length 100 cm

Please note:
Apart from the US-English set (tagged with the letter "U") **KARL STORZ** offers additional language-specific versions of the **IMAGE1™ Camera System.** Please specify in your order the language preferred:
"**F**" = French, "**I**" = Italian, "**S**" = Spanish, "**P**" = Portuguese

Specifications:

Signal-to-Noise Ratio	AGC	Video Output	Input
- IMAGE1™ Three-Chip Camera Systems ≥ 60 dB - IMAGE1™ One-Chip Camera Systems ≥ 54 dB	Microprocessor controlled	- Composite signal at BNC socket - S-Video signal to 4 pin Mini DIN socket - RGB signal to D-Sub socket - DV signal to DV socket (only IMAGE1™ with DV module) - SDI signal to BNC socket (only IMAGE1™ with SDI module)	Keyboard for title generator, 5 pin DIN socket

Control Output/Input	Dimensions w x h x d (mm)	Weight (kg)	Power Supply	Certified to:
- KARL STORZ-SCB® at 6 pin Mini DIN socket (2x) - 3.5 mm stereo jack plug (ACC 1, ACC 2), - Serial port at RJ-11	305 x 89 x 335	2.95	100 – 240 VAC, 50/60 Hz	IEC 601-1, 601-2-18, CSA 22.2 No. 601, UL 2601-1 and CE according to MDD, protection class 1/CF

Camera System IMAGE 1™

Camera Heads

For use with IMAGE1™ Camera Control Unit 22 2000 11U1xx

IMAGE1™ A3™ Three-Chip Camera Head

22 2200 40-3/**22** 2201 40-3

22 2200 40-3	**PAL**	**IMAGE1™**
22 2201 40-3	**NTSC**	**A3™ Three-Chip Camera Head**

color systems **PAL/NTSC, autoclavable,** with integrated Parfocal Zoom Lens f = 14 – 28 mm (2x), 2 freely programmable camera head buttons, incl. plastic container for sterilizing and storage 39301 ACT

IMAGE1™ A1™ One-Chip Camera Head

22 2100 40-3/**22** 2101 40-3

22 2100 40-3	**PAL**	**IMAGE1™**
22 2101 40-3	**NTSC**	**A1™ One-Chip Camera Head**

color systems **PAL/NTSC, autoclavable,** with integrated Parfocal Zoom Lens f = 14 – 28 mm (2x), 2 freely programmable camera head buttons, incl. plastic container for sterilizing and storage 39301 ACT

IMAGE1™ S3™ Three-Chip Camera Head

22 2200 30-3/**22** 2201 30-3

22 2200 30-3	**PAL**	**IMAGE1™**
22 2201 30-3	**NTSC**	**S3™ Three-Chip Camera Head**

color systems **PAL/NTSC,** with integrated Parfocal Zoom Lens f = 14 – 28 mm (2x), 2 freely programmable camera head buttons

IMAGE1™ S1™ One-Chip Camera Head

22 2100 30-3/**22** 2101 30-3

22 2100 30-3	**PAL**	**IMAGE1™**
22 2101 30-3	**NTSC**	**S1™ One-Chip Camera Head**

color systems **PAL/NTSC,** with integrated Parfocal Zoom Lens f = 14 – 28 mm (2x), 2 freely programmable camera head buttons

Cold Light Fountains and Imaging Systems for Video-Documentation

Recommended Set according to Prof. Reda KAMEL, M. D.

20 2120 40 / **20** 2121 40

9415 N / 9419 N

20 1331 20-1

9415 NB / 9419 NB

20 1340 20

495 NA

547 M

29003 NA

Cold Light Fountains and Imaging Systems for Video-Documentation

Recommended Set according to Prof. Reda KAMEL, M. D.

20 2120 40 — 1 **KARL STORZ Endovision TELECAM® 1-Chip Camera Head, autoclavable,** color system **PAL,** with integrated Parfocal Zoom Lens, f = 14 mm–28 mm, (2x); with 2 freely programmable buttons; including sterilisation tray 39301 ACT.

or:

20 2121 40 — **Same,** color system **NTSC.**

20 2130 11 — 1 **TELECAM® SL II Camera Control Unit,** color system **PAL/NTSC,** with integrated integrated Image Processing Module and DV-output; set, ready for use.

9415 NB — **Flat Screen Monitor,** screen 15" / 38 cm, wall-mounted with VESA 100 mounting, color system **PAL/NTSC**, max. resolution 1024 x 768; input: SDI, S-Video, DVI and XGA; brightness: 270 cd/m², contrast: 400:1, power supply: 100-240 VAC, 50/60 Hz
consisting of:
9415 NG **15" TFT Flat Screen**
9415 PS **Power Supply**
400 A **Mains Cord**

9415 N — **Same,** desktop model, with pedestal

9419 NB — **Flat Screen Monitor,** screen 19" / 48 cm, wall-mounted with VESA 100 mounting, color system **PAL/NTSC**, max. resolution 1280 x 1024; input: SDI, Composite, S-Video RGB, DVI and S-XGA; brightness: 450 cd/m², contrast: 650:1, power supply: 100-240 VAC, 50/60 Hz
consisting of:
9419 NG **19" TFT Flat Screen**
9419 PS **Power Supply**
400 A **Mains Cord**

9419 N — **Same,** desktop model, with pedestal

547 M — 1 **Video Color Printer,** color system **PAL, NTSC,** power supply: 110–240 VAC, 50/60 Hz, including mains cord.

20 1331 01-1 — 1 **Cold Light Fountain XENON 300** with integrated **SCB Module,** with built-in antifog air-pump, including mains cord, BNC-connecting cable and silicone tubing set, power supply: 100–125 VAC/220–240 VAC, 50/60 Hz, ready for use.

or:

20 1340 01 — 1 **Cold Light Fountain XENON NOVA® 300,** power supply: 100–125 VAC/220–240 VAC, 50/60 Hz, including mains cord, ready for use.

495 NA — 1 **Fiber Optic Light Cable,** size 3.5 mm, length 230 cm.

29003 NA — **Mobile Video Cart, consisting of:**
29003 NAG **Basic Mobile Cart,** rides on 4 antistatic double-casters, 2 equipped with locking brakes, 1 shelf fixed, 1 shelf with mains switch, 1 shelf inclinable, 1 drawer unit with lock, 1 push bar, with large lumen cable channels integrated in both columns, 1 set of non-sliding stands, 1 camera mount.
29003 PB **Power Box** with electrical supply terminal strip with 12 plugs, 12 equipotential plugs,

Dimensions:
Mobile Cart: 700 mm x 1280 mm x 686 mm (w x h x d)
Shelf: 630 mm x 480 mm (w x d)
Caster diameter: 125 mm

Please note:
IMAGE 1™ – the First Truly Digital Endoscopic Video Camera System see pages 54–55.

Notes: