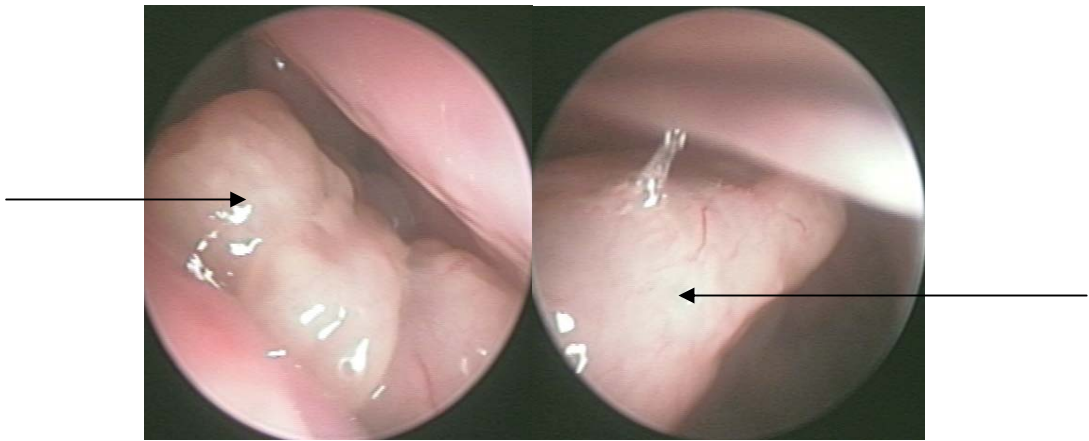


A 44 years old male presented to the center suffering from bilateral nasal obstruction. He has history of previous nasal operation with no operative details.



**Endoscopy of the nose showed:**

- Deviated nasal septum
- Bilateral hypertrophied inferior turbinate.
- Right nasal papillary mass reaching the nasopharynx

Right transnasal endoscopic excision of the mass was performed