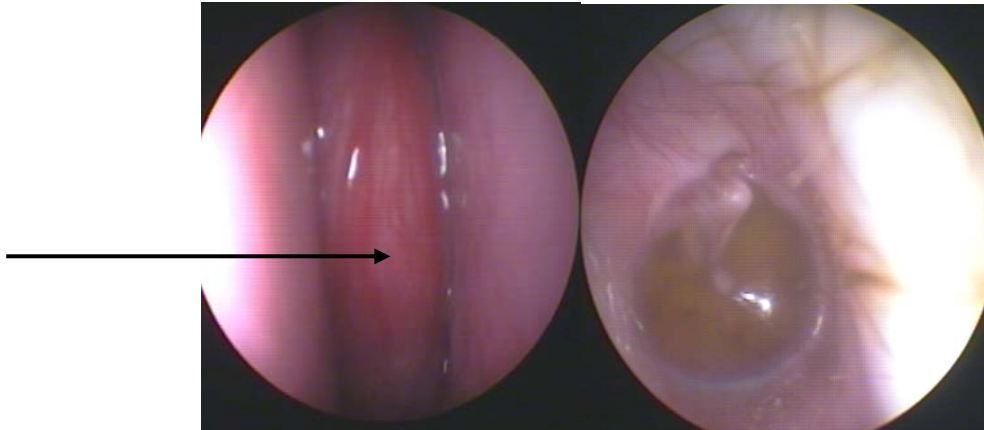


A 16 years old male presented to the center suffering from right nasal obstruction, epistaxis for 8 months.



Endoscopy of the nose showed:

- Right reddish nasal mass

Endoscopy of the ear showed:

- Right retracted drum

Endoscopic resection of juvenile angiofibroma was performed.